

# Complex Intrathoracic Tracheal Injury: A Challenging Case for Trauma Surgeons

**AUTHORS:**

Carlos H. Palacio, MD<sup>a</sup>; Matthew J. Wall, MD, FACS<sup>b</sup>; S. Rob Todd, MD, FACS<sup>b</sup>; Stephanie D. Gordy, MD, FACS<sup>b</sup>

**CORRESPONDENCE AUTHOR:**

Dr. Carlos H. Palacio  
Trauma and Acute Care Surgery  
Michael E. DeBakey Department of Surgery  
Baylor College of Medicine  
One Baylor Plaza, Room 404D  
Houston, Tx 77030  
United States  
713-798-6078  
chplmd@gmail.com

**AUTHOR AFFILIATIONS:**

a. Ben Taub Hospital  
1504 Taub Loop  
Houston, Texas 77030  
United States  
b. Michael E. DeBakey Department of Surgery  
Baylor College of Medicine  
One Baylor Plaza, MS 390  
Houston, Tx 77030  
United States

<b>Background</b>	Tracheobronchial injuries are challenging for the trauma surgeon given their low incidence. This case report evaluates the initial surgical management of a 32-year-old patient who presented with a complex tracheobronchial injury after blunt chest trauma. Prompt recognition, securing an airway, and expeditious management are critical factors to decrease the mortality of these lethal injuries.
<b>Summary</b>	A 32-year-old male presented as a trauma activation after a five hundred-pound magnet fell onto his chest. On physical exam, it was noted that the skin over his neck would elevate during inspiration and retract during expiration. Neck and chest subcutaneous emphysema were noted. A chest radiograph was performed and showed a deviated trachea. The patient was taken immediately to the operating room due to the suspicion of a tracheal injury. An awake fiber optic intubation and an orotracheal intubation failed, with aberrant anatomy noted on bronchoscopy. The patient's hypoxia worsened, and we performed a clamshell thoracotomy and obtained a surgical airway through the chest. A longitudinal laceration was noted in the membranous trachea at the level of the carina that extended cephalad. A 7 French endotracheal tube was inserted directly into the laceration and directed over to the left main bronchus. A superior extension via median sternotomy was performed. The longitudinal laceration extended up to a proximal trachea transection at the level of the second tracheal ring; these were primarily repaired, and the patient was admitted to the trauma/surgical intensive care unit.
<b>Conclusion</b>	Tracheobronchial injuries are very rare, and it is critical for the trauma surgeon to have a high index of suspicion. Early airway protection, either by intubation or the creation of a surgical airway via the neck or the chest, and anatomic exposure is crucial for exposure and repair.
<b>Keywords</b>	Tracheobronchial trauma, tracheal rupture, aerodigestive injury, trachea laceration, intrathoracic trachea injury

**DISCLOSURE:**

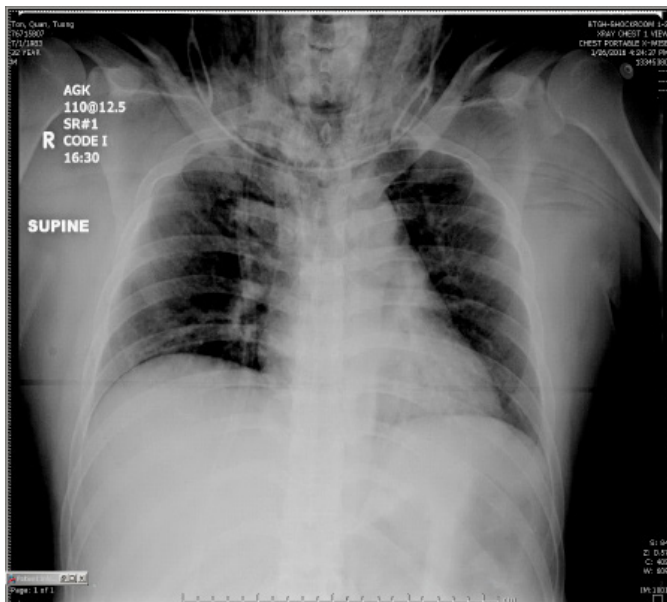
The authors have no conflicts of interest to disclose.

**To Cite:** Palacio CH, Wall MJ, Todd SR, Gordy SD. Complex Intrathoracic Tracheal Injury: A Challenging Case for Trauma Surgeons. *ACS Case Reviews in Surgery*. 2018;1(6):23-26.

## Case Description

Tracheobronchial injuries are challenging for surgeons given their low incidence and limited surgeon experience with the operative management. Historically, these injuries were lethal; however, modern improvements in prehospital care, advanced airway management, and rapid transport allow for definitive treatment at trauma centers. This case report evaluates the surgical management of a patient with a complex blunt intrathoracic tracheobronchial injury

A 32-year-old male presented after a five hundred-pound magnet fell onto his chest. The patient arrived with a non-rebreather mask and was hemodynamically stable (BP: 140/89, and pulse 98; oxygen saturations, however, was undetectable). On physical exam, his GCS was 14, he was tachypneic, phonating, and it was noted that the skin over his neck would rise during inspiration and retract during expiration. Significant neck and chest subcutaneous emphysema was also observed. A chest radiograph was performed, and a possible intrathoracic tracheal injury was suspected (Figure 1). The patient was taken immediately

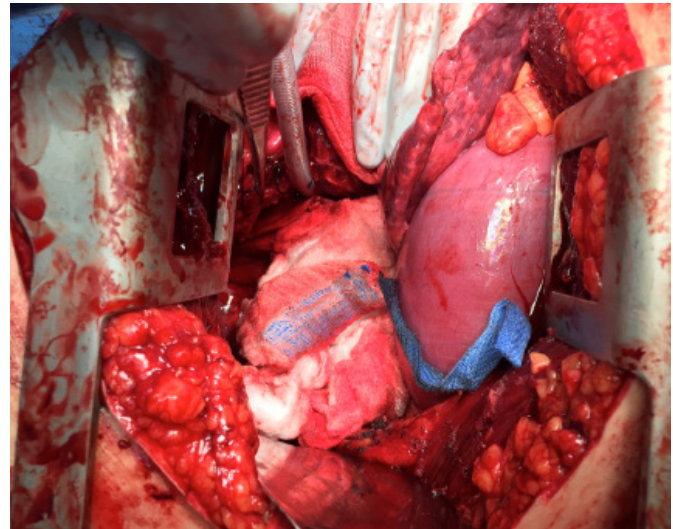


**Figure 1.** Subcutaneous emphysema and a deviated trachea

to the operating room. An awake fiber optic intubation failed, and the patient began to desaturate to the 70s. This was followed by induction and using the GlideScope; a size 7 endotracheal tube (ETT) was inserted through the cords with intermittent rise in end tidal CO<sub>2</sub>. Oxygen

saturations transiently improved to 80 percent, but then quickly dropped to the 50s, and the patient's systolic blood pressure dropped to 60. A bronchoscopy was immediately performed by anesthesia through the ETT and revealed abnormal mediastinal anatomy. Given the abnormal bronchoscopy and the patient's extremis, we had a high index of suspicion for an intrathoracic tracheal injury. Due to the possibility of additional intrathoracic injuries, a clamshell thoracotomy was our incision of choice.

Upon entering the thorax, there was a tense, bullous pneumomediastinum, which was opened. There was no injury to the heart, major vessels, or the lungs. The right lung was reflected medially and the azygos vein was divided. The tracheoesophageal groove was dissected, and a long



**Figure 2.** ETT is entering directly through the injury into the left main bronchus.

posterior tracheal laceration was identified. A 7 Fr ETT was passed through the injury into the left main bronchus (Figure 2). Saturations improved to 89 percent and cardiothoracic surgery was consulted. The membranous tracheal laceration extended cephalad, and the clamshell incision was extended cephalad via a median sternotomy. The trachea was also noted to be transected in the neck. An end-to-end anastomosis of the proximal trachea was performed as well as a primary repair of the posterior tracheal laceration. A Cook catheter was fed superiorly through the repair and an orotracheal ETT was advanced over the catheter up to the carina. The patient was then closed and resuscitated in the trauma/surgical intensive care unit.

## Discussion

Blunt tracheobronchial injuries are uncommon and often lethal.<sup>1</sup> The mortality rate for blunt injuries approaches 63 percent versus 13 percent for penetrating injuries. Moreover, blunt mechanisms of injury and the need for an emergent airway are independent predictors of mortality.<sup>2</sup> Patients with distal tracheobronchial injuries classically present with subcutaneous emphysema and pneumothorax on chest radiograph. Our patient's radiograph revealed subcutaneous emphysema and a deviated trachea (Figure 1). Additionally, our patient presented with a unique clinical sign rarely described in the literature as the "bullfrog effect." This description is when the skin over the neck rises during inspiration and retracts during expiration.<sup>3</sup> The deviated intrathoracic trachea, subcutaneous emphysema, and bullfrog effect heightened our index of suspicion for a tracheal injury, and thus led to emergent transport to the operating room. We theorize that as our patient's intrathoracic rupture was contained in his mediastinum, his concomitant cervical transection accounted for the bull frog effect during his respirations.

Once a tracheobronchial injury is suspected, securing the airway is a critical step in the management of the patient. Endotracheal intubation or creation of a surgical airway by directly intubating the tracheal injury are both acceptable techniques. Initially, an awake fiber optic intubation was attempted, but this step failed. A second orotracheal intubation was attempted; however, bronchoscopy through this ETT revealed abnormal anatomy, and we suspected the bronchoscope was in the mediastinum. In this particular case, performing a cricothyroidotomy would have placed us above the injury, delaying definitive airway. Our suspicion of intrathoracic airway injury coupled with worsening hypoxia and hypotension prompted us to perform a clamshell thoracotomy. In a retrospective study of blunt tracheobronchial injuries (n=259), right-sided bronchial injuries were more common (47 percent versus 32 percent) and were associated with a higher mortality rate (16 percent versus 8 percent,  $p=0.004$ ) when compared to the left side. Furthermore, the mortality of patients with a ruptured trachea was 26 percent.<sup>4</sup> For confirmed right sided injuries, a right posterolateral thoracotomy is the preferred approach. The distal left main stem bronchus is best approached through a left posterolateral thoracotomy.<sup>5</sup> We elected to perform a clamshell thoracotomy in this scenario due to the possibility of additional associated injuries and our belief that traumatic arrest was imminent. A key step during this exposure is retracting the right lung medially and dividing the azygos vein. This allows for dissection of the tracheoesophageal groove and exposure of the distal trachea and right main bronchus.

Once the airway is secure, defining the location and extent of the injury is the next critical step. More than 80 percent of blunt tracheobronchial injuries occur within 2.5 cm of the carina.<sup>6</sup> In our patient, we found a complex injury consisting of a long posterior tracheal laceration that extended cephalad up to the second ring in the neck where the trachea was additionally transected. We consulted with cardiothoracic surgery to assist, and our incision was extended cephalad via a median sternotomy. Some authors recommend a cervical incision for proximal tracheal injuries and a median sternotomy for suspected great vessel injuries.<sup>5,6</sup> Once we located the proximal tracheal transection, repair of the injury was performed with an end to end anastomosis of the proximal trachea and by primary repair of the distal posterior trachea. We then passed a Cook catheter through the repair and advanced an ETT over it. The thoracotomy was closed, and the patient was transported to the surgical intensive care unit for further resuscitation.

Our patient then had a prolonged hospital course and developed acute respiratory distress syndrome (ARDS). He additionally developed a tracheoesophageal fistula and a mediastinal abscess that was subsequently treated with a stent and a right VATS to drain the abscess. He was discharged to an LTAC a month after his injury and then was discharged home. There is a paucity of data regarding the long-term morbidity and mortality for blunt tracheobronchial injuries. In a retrospective series of 32 patients, Baci et al reported a 30 percent mortality for patients with blunt tracheal injuries. The mean follow-up for this series was 11.8 months. Three patients developed tracheal stenosis. The majority of patient mortality was attributed to complications from ARDS.<sup>7</sup>

## Conclusion

Tracheobronchial injuries are uncommon and often lethal. Astute clinical exam, rapid airway securement, and adequate surgical exposure are critical to identify and repair these injuries.

## Lessons Learned

Identification of extensive subcutaneous emphysema of the upper chest and neck are critical clues for a major airway injury. An airway can be secured by passing an ETT directly through the injury in the neck or the chest. Division of the azygos vein is a key maneuver for exposure of the posterior mediastinum.

## References

1. Cassada DC, Muniyikwa MP, Moniz MP, et al. Acute injuries of the trachea and major bronchi: importance of early diagnosis. *Ann Thoracic Surg* 2000; 69:1563-1567.
2. Bhojani RA, Rosenbaum DH, Dikmen E, et al. Contemporary assessment of laryngotracheal trauma. *J Thorac Cardiovasc Surg*. 2005; 130(2):426-43.
3. Sanchez LD, Ban KM. A 29 year old man with subcutaneous emphysema of the neck following blunt trauma. *Intern Emerg Med*. 2007; 2:50-52.
4. Kiser AC, O'Brien SM, et al. Blunt tracheobronchial injuries: treatment and outcomes. *Ann Thorac Surg*. 2001; 71:2059-65.
5. DuBose JA, O'Connor JV, Scalea TM. Lung, Trachea, and Esophagus. In: Moore EE, Feliciano DV, Mattox KL, ed. *Trauma, 8e*. New York, NY: McGraw-Hill; 2017.
6. Johnson SB. Tracheobronchial injury. *Semin Thorac Cardiovasc Surg*. 2008; 20(1):52-57.
7. Balci AE, Eren N, Eren S, Ulku R. Surgical treatment of post-traumatic injury tracheobronchial injuries: a 14-year experience. *Eur J Cardiovasc Surg*. 2002; 22:984-989.