

Plantar Flap Necrosis Following Transmetatarsal Amputation Predicted with Intraoperative Fluorescence Angiography

AUTHORS:

Steven Tohmasi, BS; Roy M. Fujitani, MD, FACS;
Carlos E. Donayre, MD; Isabella J. Kuo, MD; Nii-
Kabu Kabutey, MD

CORRESPONDENCE AUTHOR:

Nii-Kabu Kabutey, MD, FACS
Division of Vascular and Endovascular Surgery
Department of Surgery
333 City Blvd West
City Tower, Suite 1600
Orange, CA 92868
Phone: (714) 456-5453
Email: nkabutey@uci.edu

AUTHOR AFFILIATIONS:

University of California Irvine Medical Center
Division of Vascular and Endovascular Surgery
Department of Surgery
Orange, California

Background	Postoperative wound complications following transmetatarsal amputation (TMA) are common and are a significant cause of patient morbidity. TMA nonhealing can be attributed to the challenge in detecting whether the plantar flap has a sufficient blood supply. Current methods utilized to assess distal perfusion can be inaccurate and unreliable. We are reporting a case of intraoperative perfusion assessment of a plantar TMA flap using indocyanine green angiography (ICGA).
Summary	A 61-year-old diabetic male with advanced peripheral arterial disease required TMA for forefoot gangrene and osteomyelitis. During preoperative evaluation, the patient had adequate arterial inflow to the foot via the posterior tibial artery. This was confirmed by ankle-brachial indices, duplex ultrasound, and invasive angiography findings. ICGA was performed at the time of TMA closure for perfusion assessment of the plantar flap. Intraoperative ICGA examination revealed relative deficits to the lateral and medial flap edges. Intraoperative perfusion mapping predicted flap necrosis at these areas during the postoperative period.
Conclusion	This case study demonstrated that perfusion deficits to the plantar flap on intraoperative ICGA at the time of TMA closure were predictive of postoperative flap necrosis. Intraoperative ICGA could have the potential to help predict TMA viability through real-time visual assessment of distal skin perfusion in the operating room. Our findings suggest that intraoperative ICGA may serve as an adjunct to perfusion testing of amputation flaps and may help predict wound complications after TMA.
Keywords	Transmetatarsal, amputation, indocyanine green, angiography, flap

DISCLOSURE:

The authors have no conflicts of interest to disclose.

To Cite: Tohmasi S, Fujitani RM, Donayre CE, Kuo IJ, Kabutey N. Plantar Flap Necrosis Following Transmetatarsal Amputation Predicted with Intraoperative Fluorescence Angiography. *ACS Case Reviews in Surgery*. 2019;2(4):29-33.

Case Description

A 61-year-old diabetic male with peripheral arterial disease presented with wet gangrene to his right third toe. The patient was admitted and underwent invasive lower extremity angiography and amputation of the gangrenous toe. Intraoperative angiography revealed occlusion of the right anterior tibial, peroneal, and posterior tibial arteries at the mid-calf with reconstitution of the posterior tibial artery above the ankle. Percutaneous balloon angioplasty of the right posterior tibial artery and tibioperoneal trunk was performed. Postoperatively, the patient had a resting ankle-brachial index (ABI) of 1.34 on the right. Although this value was falsely elevated due to vessel calcifications, it was improved from the patient's preoperative ABI of 0.86 indicating successful endovascular therapy.

Two weeks after discharge, the patient re-presented with cellulitis and gangrene at the base of the toe amputation site. The patient was admitted due to concern for osteomyelitis and was started on intravenous antibiotic therapy. Magnetic resonance imaging of the right foot confirmed osteomyelitis of the third metatarsal head and the second and fourth digits. An arterial duplex ultrasound revealed a long segment occlusion of the right anterior tibial artery at the level of the mid-calf and complete occlusion of the right dorsalis pedis artery. The previously treated tibioperoneal trunk and posterior tibial artery remained patent with multiphasic waveforms throughout. Both ABI and duplex ultrasound findings confirmed the presence of adequate arterial inflow to the right foot via the posterior tibial artery. As such, the patient was deemed a suitable candidate for partial foot salvage and was consented for transmetatarsal amputation (TMA).

At the start of the operation, invasive angiographic images were obtained from level of the right common femoral artery down to the foot. The femoropopliteal vessels appeared patent without significant atherosclerotic burden. The anterior tibial artery was occluded at the level of the mid-calf. The dorsalis pedis artery was unable to be visualized (Figure 1). The tibioperoneal trunk and peroneal artery appeared patent with mild disease. The posterior tibial artery remained patent down into the level of the ankle and foot with no hemodynamically significant lesions (Figure 1). Within the foot, there was sufficient arterial runoff into the plantar arch as well as adequate vascularization of the forefoot (Figure 1). Given the finding of patent one vessel runoff to the foot, the surgical team proceeded with a TMA.

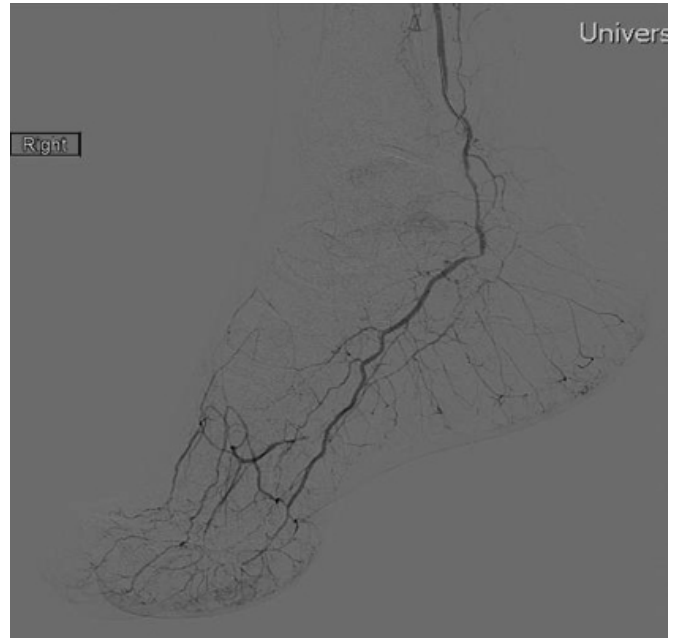


Figure 1. Invasive angiographic imaging of the right foot prior to transmetatarsal amputation revealed sufficient arterial runoff into the plantar arch and adequate vascularization of the forefoot.

The available literature describing the clinical utility of indocyanine green angiography (ICGA) for intraoperative perfusion assessment of amputation flaps is limited. Therefore, we decided to trial the SPY Elite (NOVADAQ, Bonita Springs, Florida) fluorescence imaging system for perfusion assessment of the plantar flap following TMA closure. Qualitative ICGA assessment revealed adequate perfusion to the majority of the plantar flap with significant malperfusion to the medial and lateral wound edges and along the length of the suture line (Figure 2).

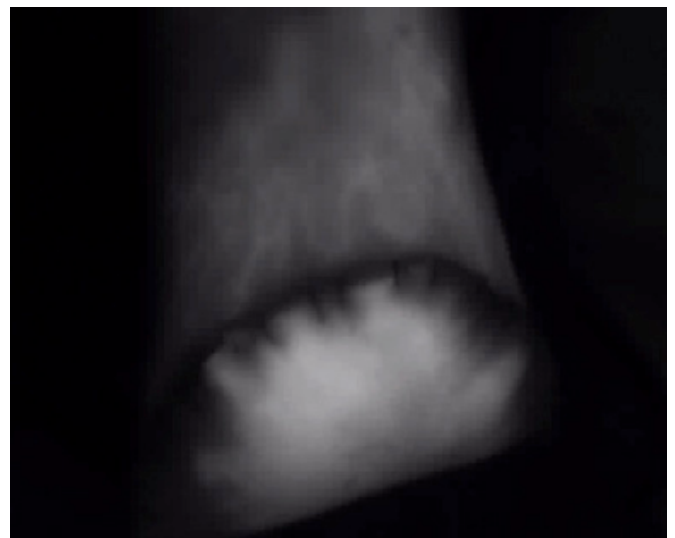


Figure 2. ICGA revealed strong perfusion to the majority of the plantar flap with significant malperfusion to the wound edges bilaterally and along the length of the suture line.

SPY Elite software was then used to assign relative perfusion units (RPU) to different regions of the plantar flap. RPU display a percentage of perfusion at a specific site in comparison to a “100 percent perfusion” reference point identified by the surgeon. Intraoperative RPU analysis showed relative perfusion percentages of 7.1 percent and 29 percent to the lateral and medial edges of the plantar flap, respectively (Figure 3). Despite these findings, the TMA skin edges did not appear compromised or in need of debridement on clinical evaluation. The surgical team opted against TMA revision due to the presence of adequate skin edges and lack of established guidelines on how to interpret ICGA findings for perfusion testing of TMA flaps.

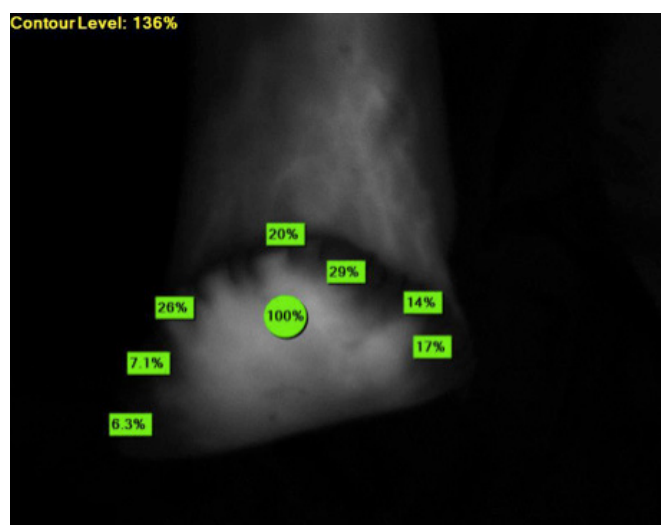


Figure 3. Relative perfusion analysis identified areas of low perfusion at the lateral and medial edges of the plantar flap.

During the early postoperative period, the patient’s amputation stump was noted to be slow healing. Eight weeks postoperatively, the patient re-presented with ischemic changes and wound breakdown at the sites that were identified as malperfused on intraoperative ICGA. The patient’s TMA stump failed to heal by primary intention and developed necrosis at the lateral and medial edges. Invasive angiography was performed upon initial findings of poor wound healing and confirmed that the posterior tibial artery remained patent. Wound cultures were also negative for any contributing infectious process. Over the course of the next six months, the TMA site required multiple surgical debridements, negative-pressure wound therapy, and split-thickness skin grafting. Additional below-knee percutaneous revascularization had to be performed to achieve complete healing of the skin grafted TMA stump.

Discussion

TMA stump complications due to malperfusion results in revision surgeries and more proximal amputations.¹⁻³ Using data from 1,205 TMA cases in the 2005–2010 American College of Surgeons National Surgical Quality Improvement Program (ACS NSQIP) database, O’Brien et al. found that 26.4 percent of the TMA cases performed required reoperation within 30 days of the initial procedure.¹ Similarly, a retrospective review of TMA cases at the Dallas VA Medical Center from 1997 to 2006 revealed that only 18 percent of patients underwent a single operation, while 56 percent of cases required revision to a more proximal level.² As there is significant patient morbidity and financial burden attached to TMA nonhealing, further investigation is warranted into novel approaches to decrease postoperative wound complications caused by inadequate peripheral arterial circulation.

The high rate of TMA failure can be attributed to the challenge in predicting healing success rates using the current methods of vascular assessment. Current techniques to determine the degree of plantar flap perfusion rely on subjective evaluation of capillary refill time, skin temperature, and tissue color. ABI is a commonly used quantitative method to evaluate lower extremity arterial perfusion. However, it is well known that systolic blood pressure recordings in diabetics can be falsely elevated due to medial arterial calcification. ABI alone may be a relatively unreliable decision-making instrument for predicting whether a TMA will heal.⁴ Prior studies have shown that toe-brachial pressure indices, arterial spectral waveforms, and transcutaneous oxygen pressure measurements may be useful predictors of amputation site healing.^{4, 5} Duplex ultrasonography and angiography are also useful for selecting the optimal lower extremity amputation level by identifying stenotic or occlusive arterial lesions that may impede wound healing. However, all of these imaging modalities provide the surgeon with a limited profile of skin surface perfusion, making it difficult to predict if there is truly enough blood flow to the amputation site to permit complete wound healing.

ICGA allows for real-time assessment of tissue perfusion in a qualitative and quantitative fashion. It has previously been shown useful for assessing flap perfusion, predicting post-operative necrosis in mastectomy flaps, and evaluating changes in foot perfusion following lower extremity revascularization for critical limb ischemia.⁶⁻¹² However, the clinical usefulness of ICGA in examining plantar flap perfusion and predicting TMA nonhealing is not clearly defined at this time. A pilot study of three above-knee

and seven below-knee amputations by Zimmermann et al. found that stump perfusion deficits on ICGA within a period of 72 hours postoperatively accurately predicted poor wound healing and the need for a more proximal amputation.¹³ In a retrospective review of 17 cases in which intraoperative ICGA was used during lower extremity amputation, Yang et al. concluded that a RPU of ≤ 31 percent displayed 100 percent sensitivity and specificity for skin flap necrosis.¹⁴

This case study demonstrated that perfusion deficits to the plantar flap on intraoperative ICGA at the time of TMA closure were predictive of postoperative flap necrosis. Intraoperative RPU analysis displayed relative perfusion percentages of 7.1 percent and 29 percent at the lateral and medial edges of the plantar flap, respectively, as well as significant ischemia along the suture line. Postoperatively, the patient developed ischemic changes and wound breakdown at the sites identified with low RPU on intraoperative ICGA. While this case study is limited to only a single patient, these findings suggest that intraoperative ICGA could potentially serve as an adjunct to perfusion assessment of the plantar flap during TMA. Intraoperative ICGA may also have the potential to predict wound complications after TMA.

We believe that further study is needed to determine if intraoperative ICGA can reliably predict plantar flap viability and decrease the incidence of wound complications following TMA. Utilization of intraoperative ICGA with TMA may aid with surgical decision-making by allowing the surgeon to identify flap malperfusion and the need for revision or conversion to a more proximal amputation level.

Conclusion

Postoperative wound complications following TMA are common and are a significant cause of patient morbidity. This case study demonstrated that perfusion deficits to the plantar flap on intraoperative ICGA at the time of TMA closure were predictive of postoperative flap necrosis. Our findings suggest that intraoperative ICGA may serve as an adjunct to perfusion testing of amputation flaps and may help predict wound complications after TMA.

Lessons Learned

Intraoperative ICGA may have the potential to help predict TMA viability through real-time visual assessment of distal perfusion in the operating room.

References

1. O'Brien PJ, Cox MW, Shortell CK, Scarborough JE. Risk factors for early failure of surgical amputations: An analysis of 8,878 isolated lower extremity amputation procedures. *J Am Coll Surg*. 2013;216:836–42. doi:10.1016/j.jamcollsurg.2012.12.041.
2. Anthony T, Roberts J, Modrall JG, et al. Transmetatarsal amputation: assessment of current selection criteria. *Am J Surg*. 2006;192. doi:10.1016/j.amjsurg.2006.08.011.
3. Pollard J, Hamilton GA, Rush SM, Ford LA. Mortality and morbidity after transmetatarsal amputation: Retrospective review of 101 cases. *J Foot Ankle Surg*. 2006;45:91–7. doi:10.1053/j.jfas.2005.12.011.
4. Caruana L, Formosa C, Cassar K. Prediction of wound healing after minor amputations of the diabetic foot. *J Diabetes Complications*. 2015;29:834–7. doi:10.1016/j.jdiacomp.2015.05.001.
5. Bacharach JM, Rooke TW, Osmundson PJ, Glociczki P. Predictive value of transcutaneous oxygen pressure and amputation success by use of supine and elevation measurements. *J Vasc Surg*. 1992;15:558–63. doi:10.1016/0741-5214(92)90196-F.
6. Gurtner GC, Jones GE, Neligan PC, et al. Intraoperative laser angiography using the SPY system: review of the literature and recommendations for use. *Ann Surg Innov Res*. 2013;7:1. doi:10.1186/1750-1164-7-1.
7. Yeoh MS, Kim DD, Ghali GE. Fluorescence Angiography in the Assessment of Flap Perfusion and Vitality. *Oral Maxillofac Surg Clin North Am*. 2013;25:61–6. doi:10.1016/j.coms.2012.11.004.
8. Giunta RE, Holzbach T, Taskov C, et al. Prediction of flap necrosis with laser induced indocyanine green fluorescence in a rat model. *Br J Plast Surg*. 2005;58:695–701. doi:10.1016/j.bjps.2005.02.018.
9. Phillips BT, Lanier ST, Conkling N, et al. Intraoperative Perfusion Techniques Can Accurately Predict Mastectomy Skin Flap Necrosis in Breast Reconstruction: Results of a Prospective Trial. *Plast Reconstr Surg*. 2012;129:778e–788e. doi:10.1097/PRS.0b013e31824a2ae8.
10. Munabi NCO, Olorunnipa OB, Goltsman D, Rohde CH, Ascherman JA. The ability of intra-operative perfusion mapping with laser-assisted indocyanine green angiography to predict mastectomy flap necrosis in breast reconstruction: A prospective trial. *J Plast Reconstr Aesthetic Surg*. 2014;67:449–55. doi:10.1016/j.bjps.2013.12.040.

11. Colvard B, Itoga NK, Hitchner E, et al. SPY technology as an adjunctive measure for lower extremity perfusion. *J Vasc Surg.* 2016;64:195–201. doi:10.1016/j.jvs.2016.01.039.
12. Braun JD, Trinidad-Hernandez M, Perry D, Armstrong DG, Mills JL. Early quantitative evaluation of indocyanine green angiography in patients with critical limb ischemia. *J Vasc Surg.* 2013;57:1213–8. doi:10.1016/j.jvs.2012.10.113.
13. Zimmermann A, Roenneberg C, Wendorff H, Holzbach T, Giunta RE, Eckstein HH. Early Postoperative Detection of Tissue Necrosis in Amputation Stumps With Indocyanine Green Fluorescence Angiography. *Vasc Endovascular Surg.* 2010;44:269–73. doi:10.1177/1538574410362109.
14. Yang AE, Hartranft CA, Reiss A, Holden CR. Improving Outcomes for Lower Extremity Amputations Using Intraoperative Fluorescent Angiography to Predict Flap Viability. *Vasc Endovascular Surg.* 2018;52:16–21. doi:10.1177/1538574417740048.