

Large Retroperitoneal Ganglioneuroma with Extensive Vascular and Visceral Involvement

AUTHORS:

Tham E; Amante AP; Maley W

CORRESPONDING AUTHOR:

Elwin Tham, MD
 Department of Surgery
 West Virginia University Hospital
 64 Medical Center Drive
 PO Box 9238
 Morgantown, WV 26506
 Email: elwintjh@gmail.com

AUTHOR AFFILIATION:

Department of Surgery
 Thomas Jefferson University Hospital
 Philadelphia, PA 19107

Background	A 44-year-old woman with lifelong irregular pain during bowel movements without any obvious discernible cause or pattern with recent acute worsening was referred to our practice. Workup revealed a large retroperitoneal mass with extensive involvement of neighboring viscera and vasculature.
Summary	<p>Our patient is a 44-year-old woman who presented with irregular bowel movements and abdominal pain throughout her life. She sought for additional medical attention after her symptoms worsened recently. Her abdominal pain was intermittent, localized in her upper abdomen, and often lead to bowel movements significantly impacting her quality of life. Workup of her abdominal pain included a computed tomography (CT) scan, which demonstrated a retroperitoneal mass that surrounded the aorta, encased the celiac axis, superior mesenteric artery (SMA), and portal splenic venous confluence, and elevated the pancreas, inferior vena cava, and the liver. A percutaneous biopsy of the mass established the diagnosis of ganglioneuroma.</p> <p>After multidisciplinary discussions at multiple institutions, the patient finally decided to proceed with surgical resection. Ganglioneuromas (GN) are tumors that originate from neural crest cells, occurring more commonly in adolescents and young adults. They are highly differentiated benign tumors that are typically nonmetabolic and do not contain neutrophils, intermediate cells, or mitotic figures. Before management, extensive preoperative surgical planning is necessary, especially in large masses with the involvement of neighboring viscera and vasculature.</p>
Conclusion	Extensive surgical planning prior to the surgical excision of a large GN should be performed, especially in setting of visceral and vascular involvement. Meticulous operative dissection, though demanding and challenging, is crucial for safe and complete tumor excision.
Key Words	ganglioneuroma; retroperitoneal mass; adrenal incidentalomas

DISCLOSURE STATEMENT:

The authors have no conflicts of interest to disclose.

RECEIVED: April 13, 2021**REVISION RECEIVED:** August 24, 2021**ACCEPTED FOR PUBLICATION:** January 22, 2022**FUNDING/SUPPORT:**

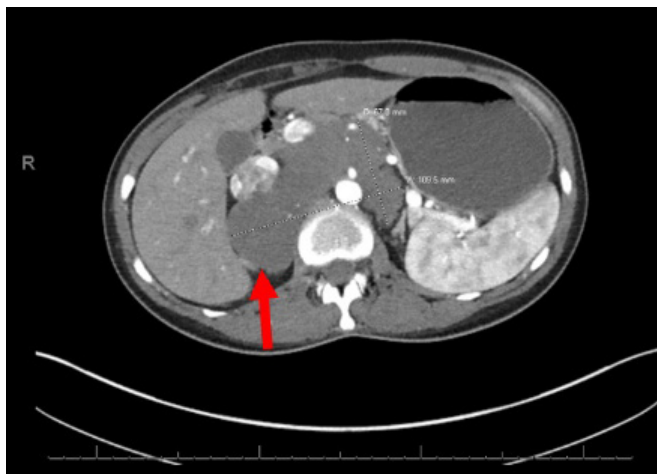The authors have no relevant financial relationships or in-kind support to disclose.

To Cite: Tham E, Amante AP, Maley W. Large Retroperitoneal Ganglioneuroma with Extensive Vascular and Visceral Involvement. *ACS Case Reviews in Surgery*. 2024;4(5):75-79.

Case Description

A 44-year-old woman with lifelong irregular abdominal pain during bowel movements without any obvious discernible cause or pattern with recent acute worsening was referred to our practice. Her past medical history included ankylosing spondylitis, for which she was treated with adalimumab. She was also seen nearly a decade prior, during which a colonoscopy performed was inconclusive. Six months before her referral, a computed tomography (CT) demonstrated a homogenous mass measuring 11.6 × 6.6 × 10.3 cm, encasing the proximal abdominal aorta, celiac axis, superior mesenteric artery (SMA), with a broad area of contact with bilateral renal arteries, splenic vein with 180-degree encasement of the inferior vena cava (IVC) and left renal vein, and elevation of the pancreas, IVC and liver. Percutaneous biopsy of the mass demonstrated a ganglioneuroma (GN), which was positive for S100 stain.

Figure 1. CT Axial Image of Retroperitoneal Mass. Published with Permission



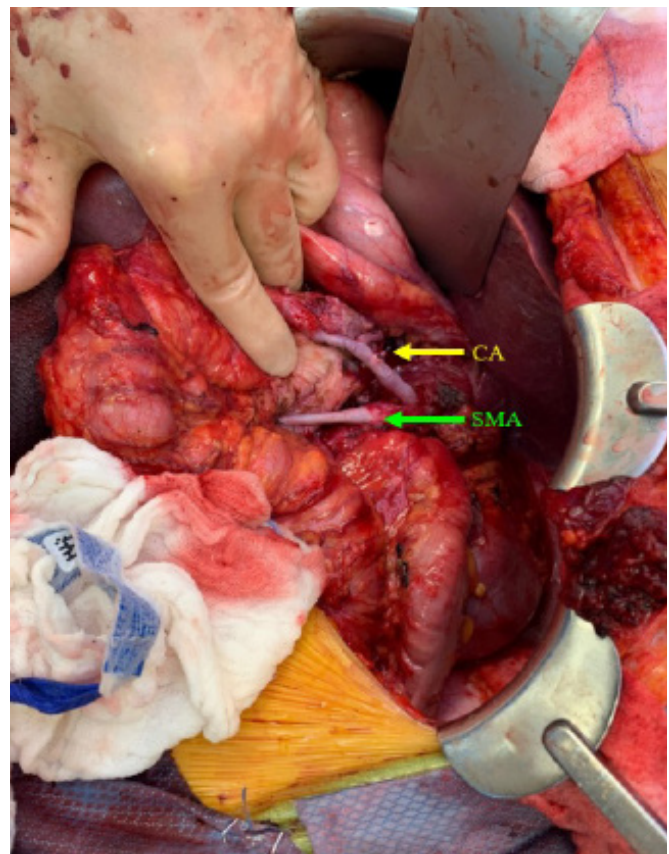
Following the diagnosis of the mass, a multidisciplinary discussion between general surgery and neurosurgery was conducted to assess its resectability. Given the extent of SMA and celiac artery encasement, the tumor would need to be debulked, and vascular reconstruction may be necessary. Risks, benefits, and alternatives were discussed, and the patient opted to proceed with surgical resection of the mass. In preparation for the surgery, her adalimumab was held.

The patient was brought to the operating room, and general anesthesia was administered. Through a Mercedes incision, the abdomen was explored. The mass was found

to be most prominent in the upper abdomen and posterior to the pancreas. Further mobilization of the spleen and pancreas with lysis of the peritoneum posterior to the spleen revealed the mass. The left adrenal gland and the kidney was localized left-sided to the mass. The splenic flexure was mobilized, and the omentum was separated from the transverse colon to allow entry into the lesser sac. The liver was then mobilized, and the vena cava could be seen elevated off the mass and out of the retroperitoneum. The liver was further mobilized off the vena cava, and the cava was fully mobilized down to the renal veins. The mass was then separated from the bilateral kidneys and adrenal glands and mobilized posteriorly. Following this, the common hepatic artery (CHA) and splenic artery were dissected out and traced back toward the celiac.

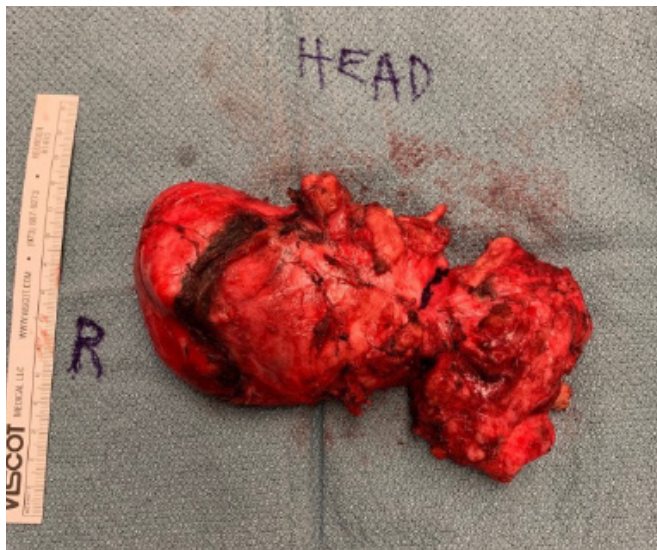The mass was seen overlying the celiac axis to a certain degree, so it was divided with electrocautery down to the celiac axis. The celiac artery was easily dissected out from the mass. Several phrenic arteries were taken, and the celiac artery was dissected back to the aorta. The right lower border of the lesion was dissected out, and the mass involved the nerves along the right renal artery.

Figure 2. Intraoperative Image of Celiac Artery (CA) and SMA After Dissection and Removal of Mass. Published with Permission



The mass was then separated from the undersurface of the pancreas with electrocautery, and eventually, the mass was entirely free and removed from the abdomen. The right renal artery was transected during dissection and mobilization, requiring resection of the injured portion and reanastomosis of the proximal and distal portion of the renal artery. A small area of the SMA was also injured and repaired with interrupted sutures with excellent Doppler signals after repair. A bipolar device was not utilized during the dissection or resection of the mass.

Figure 3. Retroperitoneal Mass After Removal. Published with Permission



Postoperatively, the patient did well without any complications. Her diet was advanced on postoperative day 2, during which she also had a return of bowel function. On postoperative day 4, her drain was removed with significant passage of ascites. A CT angiogram showed few residual ascites and patent vasculature (SMA and right renal artery). She was then discharged.

A pathologic examination of her mass revealed ganglioneuroma (WHO grade I) with minute fragments of adrenal-appearing tissue. After being discharged, the patient was readmitted multiple times for several reasons. On the first readmission, she presented to the hospital four days after being discharged with nausea and vomiting and was found to have a large fluid collection around the resection bed. This fluid was drained. Fluid studies were consistent with a chylous leak. A drain was placed by interventional radiology (IR) in the collection, and a peripherally inserted central catheter (PICC) line was placed for total parenteral nutrition (TPN) infusion. She was discharged after that.

Several weeks later, she was readmitted for diarrhea. During that admission, a colonoscopy was performed to evaluate her anemia demonstrated patchy erythema with a few scattered small aphthous ulcers in the transverse, descending, and rectosigmoid colon. This was managed medically with reinitiation of her adalimumab, after which her symptoms gradually resolved. It was theorized that she may have had an undiagnosed inflammatory bowel disease previously controlled by adalimumab.

Two weeks later, she was readmitted for nausea, abdominal pain, and diarrhea symptoms. Workup at that time revealed another fluid collection in the right pararenal space, which was drained with an IR drain. Following the placement, an interval study of the drain revealed the resolution of previously identified fluid collection.

At the follow-up after the drain study was performed, the patient reported poor appetite and oral intake. With the extensive resection of her retroperitoneal ganglioneuroma, her symptoms were theorized to be the result of possible denervation of her pylorus, so she was started on promotility agents for gastroparesis. However, attempts to treat her gastroparesis with medications were unsuccessful. A pyloric Botox injection addressed potential dysfunction, followed by a significant improvement in appetite and oral intake.

Discussion

GNs are compatible with long-term disease-free survival even with unsatisfactory surgical treatment.¹⁻² Diagnosis of a GN is determined via biopsy, and treatment is primarily surgical. A multidisciplinary approach to treating retroperitoneal GN should be considered as they commonly adhere to adjacent organs and large vessels, creating significant challenge in performing a complete resection.³ GN are rare, benign differentiated tumors originating from embryonic undifferentiated cells of the neural crest that are part of a wide spectrum of neuroblastic tumors, including neuroblastoma and ganglioneuroblastoma. They are composed of mature Schwann cells, ganglion cells, and nerve fibers and can arise anywhere along the paravertebral sympathetic plexus and occasionally from the adrenal medulla. GNs are usually located in the retroperitoneal space (32-52%), followed by the posterior mediastinum (39-43%), and less commonly in the cervical region (8-9%). They are often asymptomatic despite being large, though if symptomatic, most commonly present with abdominal pain or incidental palpation of an abdominal mass. Rarely, they may be hormonally active and cause

symptoms of hypertension, diarrhea, and virilization if catecholamines, vasoactive intestinal polypeptides, or androgenic hormones are secreted.⁴

GN are extremely rare tumors with an incidence ranging from 8.2% (8/97) to 9.4% (17/180) of adrenal incidentalomas resected in retrospective studies performed in China and Belgium.^{5,6} The notion that GN occurs more frequently in children than adults remains controversial as studies looking at more patients with GN demonstrate varied age distribution.⁵⁻⁸ As GN largely occurs in the retroperitoneum and is often initially identified as adrenal incidentalomas, preoperative diagnosis of these masses remains a challenge. Several studies have demonstrated that several CT and magnetic resonance imaging (MRI) findings may suggest GN. These include (1) lack of vascular involvement and nonenhanced attenuation <40 Hounsfield units (HU) on CT, (2) low, nonenhanced T1-weighted signal, a slightly high and heterogenous T2-weighted signal, and late enhancement on dynamic MRI.^{7,8} As GNs contain a varied composition of ganglion and Schwann cells, there is a tumor-to-tumor variation in CT and MRI findings. In a 10-year Chinese retrospective study of GN, the misdiagnosis rate was 64.7%, indicating that diagnosis of adrenal GN, especially in asymptomatic cases, remains difficult despite increased accuracy of radiologic diagnosis.⁵

On pathology, macroscopic characteristics of GN include an encapsulated mass with a firm consistency and a solid, homogeneous, grayish-white cut surface. GN can be further classified into mature and maturing types. Mature-type GNs are composed of mature Schwann cells, ganglion cells, and perineural cells. At the same time, the maturing type consists of cells with different maturation levels ranging from mature cells to neuroblasts with similar stroma. On immunohistochemical analysis, GNs are characterized by reactivity for S100, vimentin, synaptophysin, and neuronal markers such as neuron-specific enolase (NSE).

Based on the 2002 National Institute of Health (NIH) Consensus Conference on adrenal masses, adrenalectomy should be considered in patients with clinically unapparent functional adrenal tumors and those with nonfunctional adrenal incidentalomas >6 cm. Our patient presented with a large retroperitoneal mass, which may have begun as an adrenal GN though this cannot be confirmed. Management of GNs typically involves total surgical excision though it can be challenging and demanding because they tend to involve neighboring vital anatomical structures—such as in our case. In these situations, an R0 resection

is unnecessary, as aggressive resections increase the risk of injuries. In addition, a retrospective review of 32 resections of primary retroperitoneal ganglioneuroma found that of the six resections with R1 resections, the residual tumors did not progress. Two of them even shrank in subsequent examinations. The prognosis of GN after complete excision is excellent as they do not typically recur.⁹⁻¹¹

Conclusion

Extensive surgical planning is imperative prior to undertaking the excision of a large GN with extensive involvement of neighboring viscera and vasculature. A meticulous approach to operative dissection, though arduous and exacting, is critical for safe and complete tumor excision.

Lessons Learned

GN are extremely rare benign differentiated tumors. Management of GN typically involves total surgical excision though it can be challenging and demanding because of their tendency to involve neighboring vital anatomical structures. Extensive surgical planning prior to surgical excision of a large GN with extensive involvement of neighboring viscera and vasculature should be performed.

References

1. Papavramidis TS, Michalopoulos N, Georgia K, et al. Retroperitoneal ganglioneuroma in an adult patient: a case report and literature review of the last decade. *South Med J*. 2009;102(10):1065-1067. doi:10.1097/SMJ.0b013e3181b2fd37
2. Yamaguchi K, Hara I, Takeda M, et al. Two cases of ganglioneuroma. *Urology*. 2006;67(3):622.e1-622.e6224. doi:10.1016/j.urology.2005.09.024
3. Moriwaki Y, Miyake M, Yamamoto T, et al. Retroperitoneal ganglioneuroma: a case report and review of the Japanese literature. *Intern Med*. 1992;31(1):82-85. doi:10.2169/internalmedicine.31.82
4. Rha SE, Byun JY, Jung SE, Chun HJ, Lee HG, Lee JM. Neurogenic tumors in the abdomen: tumor types and imaging characteristics. *Radiographics*. 2003;23(1):29-43. doi:10.1148/rg.231025050
5. Qing Y, Bin X, Jian W, et al. Adrenal ganglioneuromas: a 10-year experience in a Chinese population. *Surgery*. 2010;147(6):854-860. doi:10.1016/j.surg.2009.11.010
6. Bin X, Qing Y, Linhui W, Li G, Yinghao S. Adrenal incidentalomas: experience from a retrospective study in a Chinese population. *Urol Oncol*. 2011;29(3):270-274. doi:10.1016/j.urolonc.2009.03.027

7. Maweja S, Materne R, Detrembleur N, et al. Adrenal ganglioneuroma. A neoplasia to exclude in patients with adrenal incidentaloma. *Acta Chir Belg.* 2007;107(6):670-674. doi:10.1080/00015458.2007.11680144
8. Lonergan GJ, Schwab CM, Suarez ES, Carlson CL. Neuroblastoma, ganglioneuroblastoma, and ganglioneuroma: radiologic-pathologic correlation. *Radiographics.* 2002;22(4):911-934. doi:10.1148/radiographics.22.4.g02jl15911
9. Vasiliadis K, Papavasiliou C, Fachiridis D, et al. Retroperitoneal extra-adrenal ganglioneuroma involving the infrahepatic inferior vena cava, celiac axis and superior mesenteric artery: A case report. *Int J Surg Case Rep.* 2012;3(11):541-543. doi:10.1016/j.ijscr.2012.07.008
10. Cocieru A, Saldinger PF. Images in surgery: retroperitoneal ganglioneuroma. *Am J Surg.* 2011;201(1):e3-e4. doi:10.1016/j.amjsurg.2010.03.012
11. Xiao J, Zhao Z, Li B, Zhang T. Primary Retroperitoneal Ganglioneuroma: A Retrospective Cohort Study of 32 Patients. *Front Surg.* 2021;8:642451. Published 2021 May 21. doi:10.3389/fsurg.2021.642451