

Obstructive Uropathy as a Reversible Cause of Acute Renal Failure in Traumatic Retroperitoneal Hematoma

AUTHORS:Link CM^a; Bunn CM^{ab}; Luchette FA^{ac}**CORRESPONDING AUTHOR:**

Fred A. Luchette, MD, MSc, FCCM, FACS
 Department of Surgery
 Loyola University Medical Center
 2160 S. 1st Avenue
 EMS Building 110, Rm. 3247
 Maywood, IL 60153
 Phone: (708) 327-3436
 E-mail: fluchet@lumc.edu

AUTHOR AFFILIATIONS:

a. Department of Surgery
 Loyola University Medical Center,
 Maywood, IL 60153

b. Burn Shock Trauma Institute
 Loyola University Medical Center
 Maywood, IL 60153

c. Surgical Service Line
 Edward Hines, Jr. VA Hospital,
 Hines, IL 60141

Background	Retroperitoneal hematoma (RPH) may develop spontaneously in the setting of therapeutic anticoagulation or secondary to traumatic or iatrogenic abdominopelvic injury. In a subset of cases, these RPH may progress to cause obstructive uropathy leading to a reversible cause of acute renal failure.
Summary	A 39-year old male fell from a height of 20 feet. On arrival, he had multiple injuries, including a pelvic ring fracture. On hospital day (HD) 2, a pulmonary embolism was diagnosed and required therapeutic anticoagulation. Following operative fixation of the pelvic fracture on HD 5, new-onset oliguric renal failure was diagnosed. Imaging studies revealed interval development of a pelvic RPH and bilateral hydronephrosis. He returned to the operating room for retroperitoneal exploration and evacuation of the pelvic hematoma. Following reoperation, renal function returned to normal while anticoagulation was continued.
Conclusion	Acute renal failure due to an RPH causing obstructive uropathy is a rare but reversible complication after injury.
Key Words	retroperitoneal hematoma; obstructive uropathy; renal failure

DISCLOSURE STATEMENT:

The authors have no conflicts of interest to disclose.

RECEIVED: June 8, 2020**ACCEPTED FOR PUBLICATION:** July 9, 2020**FUNDING/SUPPORT:**

The authors have no financial relationships or in-kind support to disclose.

To Cite: Link CM, Bunn CM, Luchette FA. Obstructive Uropathy as a Reversible Cause of Acute Renal Failure in Traumatic Retroperitoneal Hematoma. *ACS Case Reviews in Surgery*. 2021;3(4):14-16.

Case Description

Acute kidney injury (AKI), defined as the acute decline in renal function, has been reported to occur in as many as 23.8 percent of severely injured patients.¹ In patients with a major pelvic fracture, there is disruption of the presacral venous plexus and major veins, resulting in a retroperitoneal hematoma (RPH).² While an RPH in the setting of trauma typically evolves before operative repair of the pelvic injury,³ there remains potential for the development of a delayed or iatrogenic RPH. If large enough, the RPH may compress the distal ureter and impair renal function. We report an uncommon case of AKI secondary to obstructive uropathy due to an RPH that occurred in the setting of therapeutic anticoagulation in a patient with a pelvic fracture. Prompt evacuation of the RPH relieved the ureteral obstruction and restored renal function.

A 39-year-old male presented as a Level 1 trauma activation after falling approximately 20 feet off a bridge. His injuries included fractures of left ribs 5 through 12, left acetabular fracture of anterior and posterior columns extending into the ilium, displaced right superior and inferior pubic rami fractures, and fracture of the left orbital roof. On hospital day (HD) 2, a left lobar pulmonary embolism was diagnosed, and therapeutic anticoagulation was initiated without complications. On HD 6, the pelvic fractures were operatively stabilized. Six hours after surgery, anticoagulation with heparin was restarted.

Forty-eight hours later (HD 8), there was an acute rise in the serum creatinine (Figure 1A) with decreasing urine output (Figure 1B). The next day, the AKI progressed to oliguria despite aggressive resuscitation, including seven units of blood for acute blood loss anemia (Figure 1C).

A noncontrast computed tomography (CT) scan was obtained to investigate the etiology of the hemorrhage. This revealed a new RPH with a decompressed bladder and bilateral hydronephrosis (Figure 2). Additional studies confirmed that the AKI was due to obstructive uropathy due to the RPH. Therefore, he returned to the operating room for evacuation of the RPH and exploration for a vascular source of the hemorrhage. Approximately 650cc of hematoma was evacuated. Bleeding from a perivesical arterial branch was controlled with hemoclips.

Figure 1. Patient Creatinine, Urine Output, and Hemoglobin Measurements by Hospital Day. Published with Permission

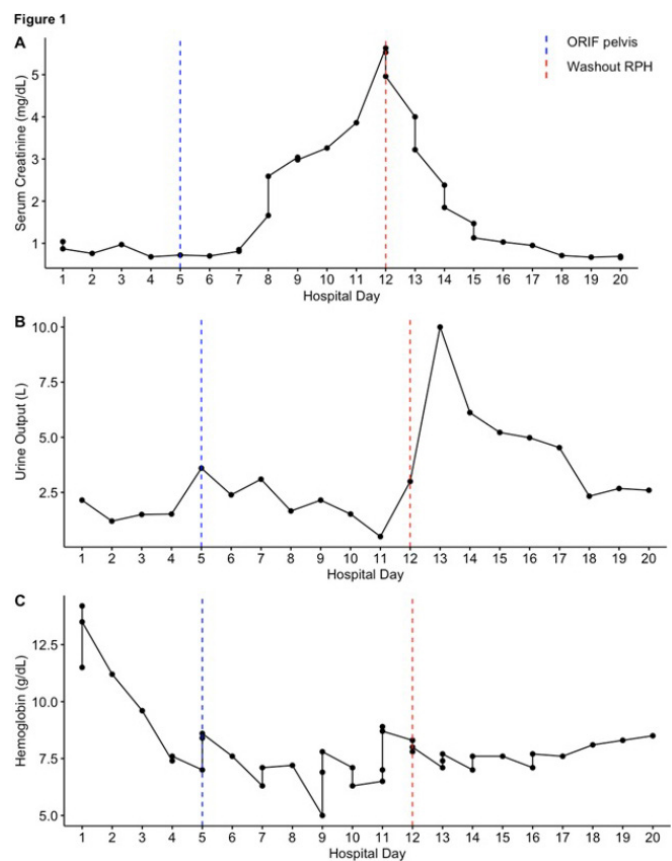
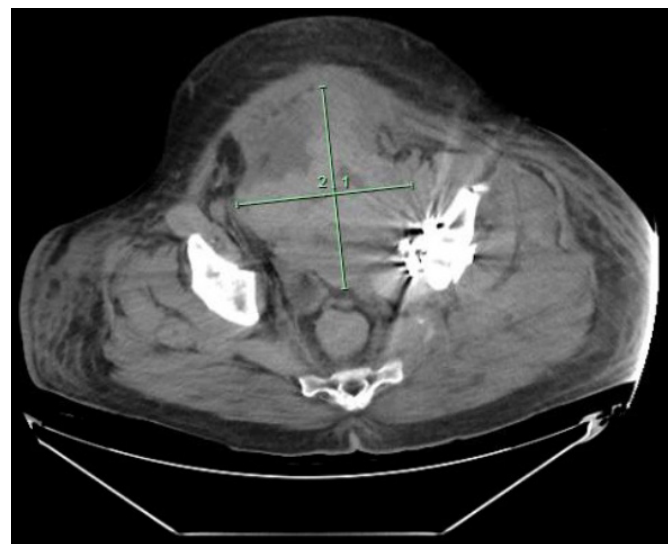


Figure 2. Axial CT Images Obtained on Hospital Day 12 Demonstrating Pelvic Hematoma Measuring 14.33 cm × 12.40 cm. Published with Permission



Following the operation, he required 10 liters of crystalloid to correct the post-obstructive diuresis. Over the next 24 hours, the hemoglobin remained stable, and anticoagulation was restarted. The AKI resolved over the next five days. Three weeks after admission, he was transferred to a rehabilitation facility with stable hemoglobin and normal renal function.

Discussion

There are multiple etiologies of AKI in trauma patients, including renal parenchymal injury, hypovolemic shock, rhabdomyolysis, obstruction, multiorgan failure/sepsis, and nephrotoxic medications.^{4,5} Hypoperfusion is known to be a common cause of AKI in critical illness and is commonly secondary to hypovolemia or other etiologies of shock.^{6,7} However, in a patient with pelvic injuries, it is imperative also to consider postrenal obstruction secondary to a retroperitoneal hematoma resulting from a pelvic fracture as this is a potentially reversible cause of oliguric renal failure.

In the therapeutically anticoagulated patient, the development of a pelvic hematoma has been described after the patient undergoes any number of procedural interventions. Frequently, the obstruction can be resolved by the placement of ureteral stents and temporary discontinuation of anticoagulants.^{8,9} However, there are instances in which even temporary interruption of therapeutic anticoagulation is detrimental. In these patients, it is prudent to proceed early with operative exploration and management of bleeding. Early surgical intervention acts to relieve the current obstruction due to the hematoma and evaluate and control the source of hemorrhage.

We recommend that prompt diagnosis and operative management of obstructive uropathy resulting from a pelvic hematoma related to pelvic injury allows restoration of kidney function and prevention of the need for renal replacement therapy.

Conclusion

Pelvic fracture is a common injury after blunt trauma. We present a case of acute renal failure due to compressive obstructive uropathy. Early operation to evacuate the hematoma allows for restoration of renal function. This case highlights the importance of a broad differential diagnosis of renal failure in trauma patients and prompt surgical treatment if indicated.

Lessons Learned

Obstructive uropathy with acute kidney injury may be due to an RPH in the setting of acute hemorrhage in trauma patients. Potential etiologies for RPH include iatrogenic and/or traumatic abdominopelvic injury and therapeutic anticoagulation. Operative management can successfully restore renal function, as demonstrated in our patient.

References

1. Vivino G, Antonelli M, Moro ML, et al. Risk factors for acute renal failure in trauma patients. *Intensive Care Med.* 1998;24(8):808-814. doi:10.1007/s001340050670
2. Hötter U, Rommens PM. Postrenal anuria in pelvic or acetabular injury: a report of three cases. *J Trauma.* 1996;41(5):916-919. doi:10.1097/00005373-199611000-00032
3. Rachmani R, Levi Z, Zissin R, Bernheim J, Korzets Z. Acute renal failure and paraplegia in a patient with a pelvic-ring fracture. *Nephrol Dial Transplant.* 2000;15(12):2050-2052. doi:10.1093/ndt/15.12.2050
4. Morris JA Jr, Mucha P Jr, Ross SE, et al. Acute posttraumatic renal failure: a multicenter perspective. *J Trauma.* 1991;31(12):1584-1590. doi:10.1097/00005373-199112000-00003
5. Liaño F, Pascual J. Epidemiology of acute renal failure: a prospective, multicenter, community-based study. Madrid acute renal failure study group. *Kidney Int.* 1996;50(3):811-818. doi:10.1038/ki.1996.380
6. Uchino S, Kellum JA, Bellomo R, et al. Acute renal failure in critically ill patients: a multinational, multicenter study. *JAMA.* 2005;294(7):813-818. doi:10.1001/jama.294.7.813
7. Wan L, Bagshaw SM, Langenberg C, Saotome T, May C, Bellomo R. Pathophysiology of septic acute kidney injury: what do we really know?. *Crit Care Med.* 2008;36(4 Suppl):S198-S203. doi:10.1097/CCM.0b013e318168ccd5
8. McBeth PB, Dunham M, Ball CG, Kirkpatrick AW. Correct the coagulopathy and scoop it out: complete reversal of anuric renal failure through the operative decompression of extraperitoneal hematoma-induced abdominal compartment syndrome. *Case Rep Med.* 2012;2012:946103. doi:10.1155/2012/946103
9. Abdulwahab AA, Hassan S, Al-Nuaim L, Abdel Halim R. Pelvic hematoma resulting in obstructive uropathy. *Saudi Med J.* 2003;24(11):1254-1255.