

Colorectal Cancer Recurrence Isolated to the Abdominal Wall Recurring 11 Years after Right Hemicolectomy

AUTHORS:

Jahanzeb Kaikaus, BA; Kristine Makiewicz, MD;
Keith Millikan, MD

CORRESPONDENCE AUTHOR:

Jahanzeb Kaikaus
MD Candidate Class of 2019
1314 W Fillmore St, #B
Chicago, IL 60607
(502)-299-5510
Jahanzeb_Kaikaus@rush.edu

AUTHOR AFFILIATIONS:

Rush University Medical Center
Department of Surgery
1725 W Harrison St, Suite 810
Chicago, IL 60612

Background	A female patient presented 11 years following right hemicolectomy for Stage II colorectal carcinoma recurring in the abdominal wall.
Summary	The patient is a 61-year-old female with a past medical history of Stage II (T3N0M0) ascending colon carcinoma in remission. She presented regarding resection of an abdominal wall mass testing positive for metastatic colonic adenocarcinoma 11 years after her primary diagnosis. The patient had undergone the appropriate treatment and follow-up regimen according to the standard of care for her original cancer, including right hemicolectomy and subsequent chemotherapy. Thus, her subsequent diagnosis of metastatic disease was unique based both on timeframe and location. There is minimal literature detailing such a presentation of colon adenocarcinoma. The lesion was resected and required abdominal wall reconstruction with mesh. Final pathology yielded a moderately differentiated adenocarcinoma.
Conclusion	Recurrence of colorectal carcinoma isolated to the abdominal wall is a rare occurrence. We present a case of recurrence occurring 11 years after original resection of the diseased colon distant from the incisional site. The presented case emphasizes both the need for consistent follow-up with surgically treated cancer patients and the need for further research at a cellular level to identify the mechanism of such occurrences.
Keywords	Hemicolectomy, colorectal adenocarcinoma, metastasis, abdominal wall reconstruction, mesh

DISCLOSURE:

The authors of this paper have no conflicts of interest to disclose.

To Cite: Kaikaus J, Makiewicz K, Millikan K. Colorectal Cancer Recurrence Isolated to the Abdominal Wall Recurring 11 Years after Right Hemicolectomy. *ACS Case Reviews in Surgery*. 2018;2(2):10-13.

Case Description

The patient is a 61-year-old Caucasian female with a past medical history of Stage IIB (T3N0M0), grade II colon carcinoma in remission who presented to Rush University Medical Center Department of General Surgery regarding resection of an abdominal wall mass testing positive for isolated metastatic colonic adenocarcinoma almost 11 years after her original diagnosis. Over the prior few months, the patient described progressive discomfort and pain in the right side of her lower abdomen, and a palpable, growing mass presented as a diffuse induration and tenderness in the right lower quadrant. An incisional biopsy confirmed the diagnosis of adenocarcinoma via staining. Histologically, the sample was consistent with colon carcinoma.

In 2006, the patient had a right hemicolectomy and adjuvant chemotherapy for Stage IIB (T3N0M0) colon cancer at an outside hospital. Her chemotherapy regimen consisted of 10 cycles of FOLFOX, and she has since followed up on regular intervals with her oncology team. Following her re-diagnosis in June 2017, CAT scans of the neck, chest, abdomen, and pelvis were performed as well as a PET scan showing the disease localized solely to the abdominal wall at a site separate from any prior surgical incisions. She had a colonoscopy that was unremarkable. CA19-9, CA125, and CEA values were obtained and were within normal limits. Unfortunately, values for these markers from her previous diagnosis were unavailable for comparison. It was decided that en bloc resection of the mass was feasible.

Surgery was performed using an open approach, during which an abdominal mass was found in the right rectus abdominis extending laterally into the external and internal oblique muscles. Flaps were raised superiorly to the umbilicus, medially to the midline, inferiorly to the inguinal ligament and laterally to the anterior superior iliac spine. Posteriorly, most of the dissection was in the pre-peritoneal space except for a small area directly posterior to the tumor that required resection of a small section of peritoneum and omentum. The specimen taken was approximately 10 cm in length (Figure 1). Following excision, the defect created was repaired with mesh. The mesh was placed in an inlay fashion and was tacked to the ASIS and pubic tubercle using orthopedic screws.

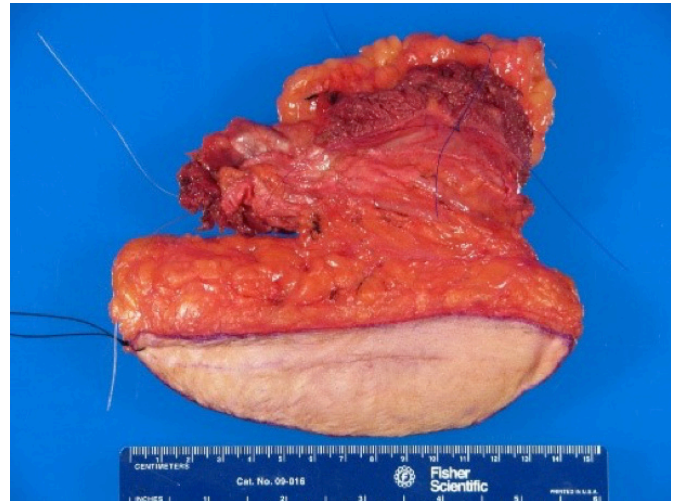

Figure 1. Pathologic specimen consisting of metastatic colon adenocarcinoma embedded within the abdominal wall.

The final pathology report of the specimen was obtained and indicated “metastatic moderately differentiated adenocarcinoma of unknown origin. Surgical margins were negative for malignancy.” Immunohistochemistry performed on the neoplastic cells were positive for CK19, partially positive for CDX-2, and negative for CK7 and CK20. Histological appearance of the specimen is provided in Figure 2.

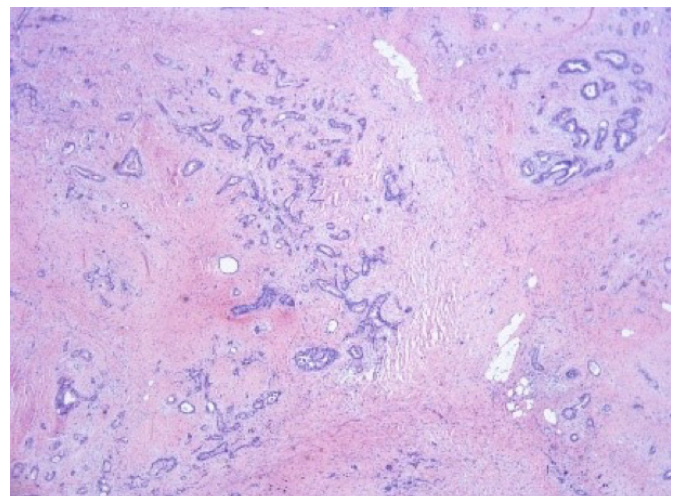


Figure 2. Histological appearance of obtained abdominal wall specimen demonstrative of adenocarcinoma.

This patient has no other personal cancer history. Her other past medical history includes carotid artery stenosis, cholelithiasis, CAD, MI in 2009, hypertension, and diabetes. She has an extensive smoking history. Her family history consists of lung cancer in her father, hepatobiliary and bladder cancer in her brothers, and ulcerative colitis in her daughter.

Discussion

Approximately 30 percent of colorectal cancer patients have a complicated course involving metastasis.¹ The incidence of isolated colonic carcinoma recurrence to the abdominal wall is quite rare in the literature. This patient's presentation is unique both in its location and the time-frame in which it occurred. Her original colon carcinoma was classified as a Stage II cancer, indicating that it had spread beyond the boundaries of the muscularis propria and possibly into adjacent tissue. However, lymph node involvement and metastasis were shown to be negative per outside hospital records. Surgical resection is the recommended approach to loco-regional colon cancer, as was done in this patient's case in 2006. Though the benefits of adjuvant chemotherapy in eliminating micrometastases in Stage II colon cancer are unclear, this patient still received 10 rounds of FOLFOX following her operation. Additionally, patients treated for Stage II colon cancer are recommended to follow up consistently for at least five years following remission per National Comprehensive Cancer Network guidelines. The patient attended regular appointments with her oncology team in the 11 years since her original diagnosis and recurrence.

The patient nevertheless developed an isolated recurrence 11 years later. This was confirmed via biopsy; the cell-surface marker CDX2 is sensitive for cancers of intestinal origin.² As mentioned above, the most common sites of colon cancer metastases are the liver, lung, and peritoneum. With regards to the liver and lung, it is intuitive that cancer cells released from the primary malignancy into the portal circulation would seed within the liver. These cells lodge and cluster over time in the venous sinusoids and become vascularized by hepatic artery blood flow. These individually developing metastases progressively enlarge to the point that their vasculature can no longer support the entire tumor, resulting in central necrosis. Eventual disruption of the capillaries supplying the metastatic growths can then release more cancer cells into the systemic circulation and seed the lungs, the next major organ system in the vascular tree. Hence, it is logical that metastatic colon cancer is often seen in these locations and why its effects are so devastating.¹

Metastasis to the peritoneum is also a realistic possibility via direct extension. The cancer, upon invading the full thickness of the bowel, could seed the peritoneum even if the peritoneal fluid tests negative. An additional mechanism by which this can occur is trauma during the operation to resect the primary tumor. This trauma may not only release cancer cells that can potentially seed distant sites, but it also produces an adhesive surface promoting cancer cell implantation within the peritoneum.

There are other areas that receive metastases to a lesser degree, including the bones, adrenal glands, and spleen. However, it seems improbable that our patient's recurrence can be explained by the aforementioned mechanisms. The mass was primarily within the abdominal wall musculature, with minimal peritoneal involvement and distinct from any prior surgical incisions. It seems unlikely for cancer cells to spread via the systemic circulation and reach the abdominal wall without seeding any other organ—and doing so 11 years later. It would also be inappropriate to deem this as a case of peritoneal carcinomatosis, as one would expect intraperitoneal disease with multiple focal lesions.¹

Interestingly, there are documented cases, though rare, of isolated abdominal-wall metastasis in colorectal cancer. Ledesma et al³ collected records of 22 such patients over a ten-year period. Thirteen of these patients demonstrated recurrent tumor in a prior midline or paramedian incision. Similar to our patient, many of these patients underwent en bloc resection with subsequent primary closure or mesh placement. The long-term outcome of the patients in their study varied based on individual characteristics of the cancer, though surgery provided some degree of benefit for all patients. Long-term outcome will continue to be monitored in the presented patient.

Other literature has documented incisional wound recurrences, though infrequently. One retrospective cohort study found this incidence following laparoscopic colectomy for Stage B2 and Stage C colorectal carcinoma to be 0.6 percent. Interestingly, the majority of these recurrences occurred in the Stage C cancer resections, and the mean time to recurrence was 1.5 years, far shorter than that seen in the patient presented here. Furthermore, most of the patients presenting with recurrence in this study demonstrated multiple sites of recurrence.⁴

Koea et al⁵ analyzed their database of patients diagnosed with colorectal cancer between 1986 and 1998 and found that 31 of these patients presented with a recurrence in the abdominal wall between 7 to 183 months following

primary surgery. As with our patient, four of these patients presented with isolated abdominal wall disease lacking any intraabdominal involvement. Perhaps of even greater interest among this cohort are those patients presenting with recurrent metastases several years later.

Not to be discounted, however, are the mechanisms occurring at a molecular level. Metastasis is a dynamic and complex process, with increasing emphasis being put on the microenvironment within which cancer cells exist and genetic variability among the cells of a tumor. The latter is a product of the inherent genetic instability of metastatic tumor cells and the selective nature of this process. This is further enhanced and expedited by the arsenal of chemotherapy treatments in modern oncology.⁶ That this has played a role in the unique timeframe of the presented patient's course must not be discounted. How these metastatic cells interacted with those in the surrounding tissue of the abdominal wall to survive and facilitate their own growth is astounding.^{7,8}

A common thread among cases of abdominal wall metastases of varying forms of cancer is recurrence at the site of surgical resection of the primary tumor. This has been reported primarily in cases of colorectal carcinoma and hepatocellular carcinoma, but also in other forms of cancer. Such an explanation appears less likely in this case, given the location of recurrence in the right lower quadrant rather than at the previous lower midline incision. Additionally, the timeframe remains a point of interest.

Conclusion

Metastasis or recurrence of colorectal carcinoma isolated to the abdominal wall is rare. We present a case of metastasis occurring 11 years after original resection of the diseased colon in the abdominal wall separate from any incision sites. The presented case emphasizes the need for consistent follow-up with surgically treated cancer patients and the need for further research at a cellular level to identify the mechanism of such occurrences.

Lessons Learned

Patients with colorectal cancer that has been surgically resected require interval follow-up for the small possibility of recurrence within the abdominal wall, among other more commonly recognized sites. Moreover, surgeons and oncologists alike must be aware of the possibility of seeding of the incisional site during resection, and care must be taken to minimize this occurrence. In cases of abdominal wall recurrence, effective reconstruction of the abdominal wall can be undertaken with mesh.

References

1. Sugarbaker PH. Colorectal Cancer: Prevention and Management of Metastatic Disease. *BioMed Res Int*. 2014;2014:1-11. doi:10.1155/2014/782890.
2. Werling RW, Yaziji H, Bacchi CE, Gown AM. CDX2, a Highly Sensitive and Specific Marker of Adenocarcinomas of Intestinal Origin. *Am J Surg Pathol*. 2003;27(3):303-310. doi:10.1097/00000478-200303000-00003.
3. Ledesma EJ, Tseng M, Mittelman A. Surgical treatment of isolated abdominal wall metastasis in colorectal cancer. *Cancer*. 1982;50(9):1884-1887. doi:10.1002/1097-0142(19821101)50:9<1884::aid-cnrc2820500939>3.0.co;2-6.
4. Reilly TW, Nelson H, Schroeder G, Wieand SH, Bolton J, O'Connell MJ. Wound recurrence following conventional treatment of colorectal cancer. *Dis Colon Rectum*. 1996;39(2):200-207. doi:10.1007/bf02068076.
5. Koea JB, Lanouette N, Paty PB, Guillem JG, Cohen AM. Abdominal wall recurrence after colorectal resection for cancer. *Dis Colon Rectum*. 2000;43(5):628-632. doi:10.1007/bf02235576.
6. Talmadge JE, Fidler IJ. AACR Centennial Series: The Biology of Cancer Metastasis: Historical Perspective. *Cancer Res*. 2010;70(14):5649-5669. doi:10.1158/0008-5472.can-10-1040.
7. Vatandoust S. Colorectal cancer: Metastases to a single organ. *World J Gastroenterol*. 2015;21(41):11767. doi:10.3748/wjg.v21.i41.11767.
8. Tarin D. Clinical and Biological Implications of the Tumor Microenvironment. *Cancer Microenviron*. 2012;5(2):95-112. doi:10.1007/s12307-012-0099-6.