

# Delayed Absorption of Oxidized Cellulose (Surgicel®) Mimicking Residual Tumor in Post-Thyroidectomy Patients

**AUTHORS:**

Puckett Y<sup>a</sup>; Doubleday A<sup>b</sup>; Olson K<sup>c</sup>; Long K<sup>b\*</sup>  
 \*Shared co-first author

**CORRESPONDING AUTHOR:**

Amanda Doubleday, DO, MBA  
 1111 Delafield Street  
 Ste. 209  
 Waukesha, WI 53188  
 Email: adoubleday@waukeshasurgery.com

**AUTHOR AFFILIATIONS:**

a. Department of Surgery  
 Division of Surgical Oncology  
 University of Wisconsin School of Medicine and Public Health  
 Madison, WI 53792

b. Department of Surgery  
 Division of Endocrine Surgery  
 University of Wisconsin School of Medicine and Public Health  
 Madison, WI 53792

c. Department of Pathology and Laboratory Medicine  
 University of Wisconsin School of Medicine and Public Health  
 Madison, WI 53792

<b>Background</b>	<p>This study investigates the potential of delayed absorption of Surgicel® (Johnson &amp; Johnson, New Brunswick, NJ), a widely used hemostatic agent composed of oxidized cellulose, to mimic a recurrent mass in post-surgical imaging for both benign and malignant thyroid conditions.</p> <p>We present a case report detailing how Surgicel® mimicked thyroid cancer recurrence. Furthermore, we aim to analyze previously documented instances through a comprehensive literature review. This analysis will assess how such occurrences were managed in prior cases.</p>
<b>Summary</b>	<p>Examining a retained oxidized cellulose (Surgicel®) case via permanent pathology sections, we employed CD68 immunostaining to identify histocytes and excluded thyroid tissue using cytokeratin and thyroglobulin stains. A comprehensive literature review (PubMed, Google Scholar) with terms like “Surgicel,” “thyroid cancer,” and “recurrence” identified three publications with seven cases of retained hemostatic agents in thyroidectomy beds. Management included observation, biopsy, and repeat surgery. All reported pathology confirmed retained oxidized cellulose with varying inflammatory markers.</p>
<b>Conclusion</b>	<p>Retained oxidized cellulose (Surgicel®) poses a potential diagnostic challenge. This presentation delves into its characteristic imaging and cytopathological features, aiding in the accurate identification of such occurrences.</p> <p>Understanding the presentation and management strategies of retained Surgicel® equips surgeons with the requisite knowledge to effectively address these situations, minimizing patient complications and the need for unnecessary re-interventions.</p>
<b>Key Words</b>	<p>thyroid cancer; Surgicel; recurrence; oxidized cellulose; thyroidectomy; ultrasound</p>

**DISCLOSURE STATEMENT:**

The authors have no conflicts of interest to disclose.

**RECEIVED:** January 14, 2022

**REVISION RECEIVED:** February 17, 2022

**ACCEPTED FOR PUBLICATION:** March 30, 2022

**FUNDING/SUPPORT:**

The authors have no relevant financial relationships or in-kind support to disclose.

**To Cite:** Puckett Y, Doubleday A, Olson K, Long K. Delayed Absorption of Oxidized Cellulose (Surgicel®) Mimicking Residual Tumor in Post-Thyroidectomy Patients. *ACS Case Reviews in Surgery*. 2024;4(7):33-38.

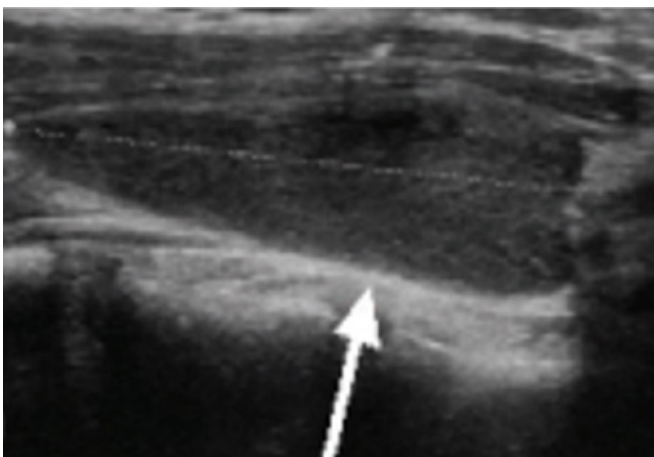
## Case Description

Oxidized regenerated cellulose (Surgicel®; Johnson & Johnson, New Brunswick, NJ) is a commonly used adjunctive absorbable hemostatic agent in thyroid surgery to assist in control of capillary, venous, and small arterial oozing when ligation or other conventional methods of control are impractical or ineffective. Its mechanism of action consists of providing a matrix for platelet adhesion and aggregation when placed on the surface of soft tissues. It is soft, lightweight, and often layered. Its absorption time is approximately two to seven days, and it completes degradation by eight weeks.<sup>1</sup> However, delayed resorption can mimic persistent tissue or tumor recurrence on imaging, posing a diagnostic challenge.

A 31-year-old female presented with a symptomatic left thyroid nodule (4.9 cm) diagnosed as benign colloid via FNA biopsy. Given the size and compressive symptoms, a left thyroid lobectomy was performed. Following specimen excision, meticulous hemostasis, and irrigation, small pieces of oxidized cellulose (Surgicel®) were used in the thyroid bed. However, the final pathology revealed follicular carcinoma, necessitating a completion thyroidectomy.<sup>2</sup>

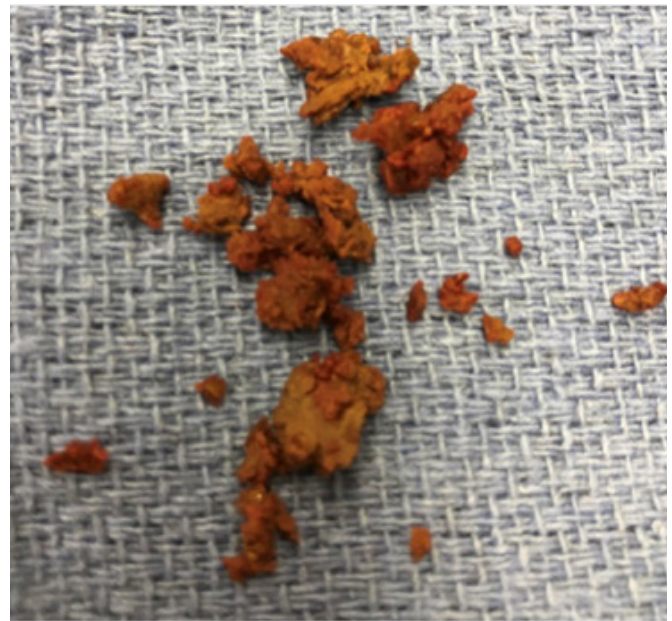
Ten weeks post-initial thyroidectomy, a preoperative ultrasound (US) identified suspected residual thyroid tissue. This finding is on the anterior left lateral aspect of the trachea, overlying the left lobectomy bed (Figure 1). This US evaluation aligns with the institution's standard protocol for pre-completion thyroidectomy assessment, aiming to detect any remnant or previously unidentified lymphadenopathy.

**Figure 1.** Residual Oxidized Cellulose (Surgicel®) Mimicking Tissue on Preoperative Ultrasound. Published with Permission



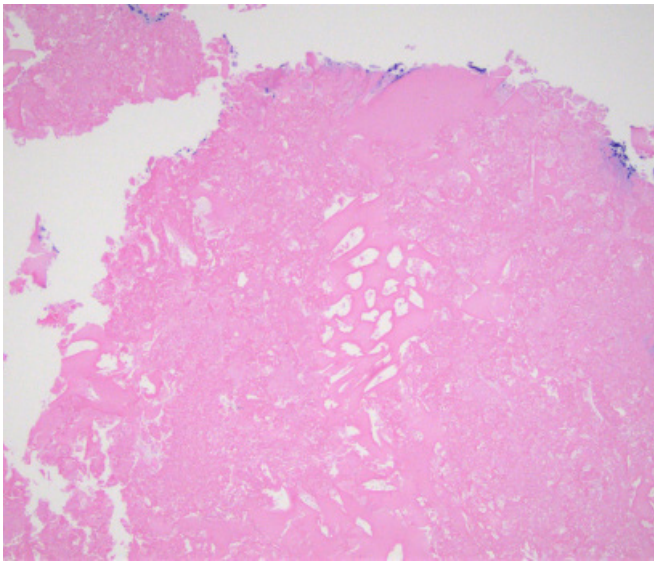
The surgeon planned to remove this retained tissue at the time of completion thyroidectomy. Approximately three months after the initial operation, the patient underwent a completion thyroidectomy, during which the retained oxidized cellulose (Surgicel®) was removed (Figure 2).

**Figure 2.** Surgicel® Retained Intraoperatively. Published with Permission



The intraoperative findings revealed a brownish mass in the left neck, lateral to the midline. This mass was readily excised, with a strong suspicion of encapsulated retained oxidized cellulose (Surgicel®). The final pathology confirmed the diagnosis: the right thyroid tissue was benign, while the left neck mass consisted solely of oxidized cellulose with entrapped histiocytes (Figure 3).

**Figure 3.** Pathology of Extracted Material from Prior Thyroidectomy Bed (H&E Stain). Published with Permission



*This image demonstrates a foreign body reaction (entrapped histiocytes) to acellular, eosinophilic material (oxidized cellulose). Note the presence of fibrinous and/or necrotic debris alongside areas of sheet-like deposits and cystic spaces. Clinicopathologic correlation confirmed the material as residual Surgicel® from the preceding surgery.*

Our review found seven cases of retained oxidized cellulose in thyroidectomy beds across three publications. This aligns with reports of retained hemostatic agents in various surgeries, especially gastrointestinal, gynecologic, thyroid, cardiac, and brain procedures.<sup>3</sup> In thyroidectomy cases, FNA biopsy typically confirms the presence of cellulose and/or necrotic material.<sup>3,4</sup> However, Liu et al. reported a case diagnosed solely by FNA and two others solely based on ultrasound findings.<sup>4</sup> Repeat surgery was needed in two cases: one due to planned completion thyroidectomy and another for protruding Surgicel®.<sup>1</sup> Further details of these reported cases are summarized in Table 1.

In our case, the residual oxidized cellulose was extracted and forwarded to pathology for permanent sectioning. Immunohistochemical staining with CD68 was employed to identify the presence of histiocytes. To definitively exclude the possibility of recurrent thyroid follicular cells, a panel of stains was utilized: cytokeratin AE1/AE3, CAM 5.2, TTF-1, and thyroglobulin. Subsequently, a literature review was undertaken to identify any documented instances exhibiting similar presentations to assess the pathological aspects, management strategies, and the broader implications of our findings and those of comparable cases. A systematic approach was adopted, utilizing PubMed and Google Scholar as search engines, employing the terms “Surgicel,” “oxidized cellulose,” “thyroid cancer,” and “mimicking recurrence.”

**Table 1.** Summary of Reported Cases of Retained Surgicel Mimicking Thyroid Cancer Recurrence

Authors	n	Age (in years)	Gender	Type of Thyroid Cancer	*ID on Imaging	Original Surgery	ID Time from Surgery	Management	Pathology
Our patient	1	31	*F	follicular carcinoma	*US	left thyroid lobectomy	3 months	completion thyroidectomy (required regardless)	oxidized cellulose with entrapped histiocytes
Liu et al. <sup>4</sup>	3	36	F	carcinoma	US	left thyroid lobectomy	23 months	US, *FNA	cellulose fragments
		67	F	carcinoma	US	total thyroidectomy	16 days	serial US; observation until resolution	*N/A
		52	*M	adenoma	US	right thyroid lobectomy	5 months	serial US; observation until resolution	N/A
Hernández-Bonilla et al. <sup>3</sup>	3	36	F	*PTC	US	thyroidectomy	24 months	FNA	acellular oxidized cellulose with inflammatory and phagocytic cells
		49	F	multinodular goiter	US	thyroidectomy	13 months	FNA	acellular oxidized cellulose with inflammatory and phagocytic cells
		35	M	follicular carcinoma	US	thyroidectomy	18 months	FNA	acellular oxidized cellulose with inflammatory and phagocytic cells
Royds et al. <sup>1</sup>	1	56	F	multinodular goiter	*PE	total thyroidectomy	10 days	surgical removal	not reported

\*F: female; M: male; US: ultrasound; FNA: fine-needle aspiration; ID: identified; PTC: papillary thyroid cancer; N/A: not available; PE: physical exam, Surgicel<sup>®</sup> was seen protruding through the wound

## Discussion

Retained oxidized cellulose (Surgicel<sup>®</sup>) following thyroid surgery poses a challenge for accurate postoperative assessment. Literature reports documented cases where Surgicel mimicked residual thyroid tissue or recurrence on imaging studies. This is particularly concerning in the current landscape of thyroid cancer management, where the 2015 American Thyroid Association (ATA) guidelines emphasize thyroid-preserving approaches.<sup>2</sup>

Misinterpretation of Surgicel<sup>®</sup> on imaging can trigger unnecessary biopsies to confirm the absence of malignancy. This exposes patients to unnecessary procedures, discomfort, and potential risks. Furthermore, it creates undue anxiety for patients, their families, and the treating surgeon.

Surgicel<sup>®</sup>, a commonly used oxidized cellulose hemostat, exhibits a well-defined degradation timeline. While most degrade within two days, complete absorption can take

up to eight weeks, often accompanied by an inflammatory response within a week.<sup>1</sup> In some cases of reported retained oxidized cellulose (Surgicel®) where FNA was performed, cytology shows only oxidized cellulose material. Several authors attribute this finding to the excessive use of oxidized cellulose (Surgicel®).<sup>1,3</sup> In our case, however, the standard amount was employed: three one-inch by three-inch squares on either side of the trachea per lobectomy bed.

Interestingly, reported cases of retained hemostatic agents typically demonstrate a type four hypersensitivity reaction, including a granulomatous subtype.<sup>1</sup> While our pathologist observed an inflammatory response suggestive of granuloma formation due to a foreign body,<sup>3</sup> the absence of excessive material usage suggests a potential cell-mediated, type four delayed hypersensitivity and histiocytic reaction.<sup>1</sup> Notably, this foreign body response can be asymptomatic, as evidenced by the majority of cases in the reviewed literature.<sup>1,3,4</sup>

In most asymptomatic cases, identification of retained oxidized cellulose (Surgicel®) in a thyroid bed can be mistaken for concerning findings. This is frequently identified through neck ultrasonography, the primary imaging method used to monitor for cancer after thyroid surgery. Understanding the distinct sonographic characteristics of Surgicel® is crucial to distinguishing it from other findings.

Typically, retained Surgicel® appears as a well-defined hypoechoic lesion with scattered punctate internal echoes on ultrasound. These lesions lack blood flow and calcifications.<sup>4,5</sup> Additionally, the sonographic features of Surgicel® tend to remain stable on serial imaging follow-up, unlike recurrent cancer. In contrast, thyroid bed cancer recurrence often manifests as hypoechoic or mixed hyper/hypoechoic, usually round or oval in shape. These malignant lesions exhibit internal vascularity and may harbor microcalcifications or even coarse calcifications.<sup>5</sup> It is essential to acknowledge that the diagnostic accuracy of ultrasonography relies heavily on operator experience and expertise.

Retained Surgicel® in the thyroidectomy bed appears most frequently detected through ultrasound analysis, as suggested by our literature review. Management strategies for this scenario vary. While minimally invasive FNA has proven successful for diagnosis in some cases, a cautious approach is necessary. Hernández-Bonilla et al. highlight the potential pitfall: minimal Surgicel® without a full-blown foreign body granulomatous reaction can mimic dense protein

material, resembling colloid commonly found in thyroid cells. Therefore, meticulous examination is crucial to identify the characteristic features of Surgicel®—thin, quadrangular, and laminated structures.<sup>3</sup>

Conservative management with observation has been described as an alternative approach.<sup>1,4</sup> While imaging studies cannot definitively diagnose retained oxidized cellulose (Surgicel®), the characteristic ultrasound findings discussed previously can lead an ultrasonographer to highly suspect this condition, especially if the operative report confirms Surgicel® usage.<sup>1,3</sup> In cases where completion thyroidectomy is necessary or when the retained material hinders wound healing, repeat surgery may become the only viable course of action.<sup>1</sup>

Surgeons and radiologists should be aware of the potential for delayed absorption of Surgicel®, an oxidized cellulose hemostatic agent. This phenomenon can mimic residual tumor or recurrence on follow-up imaging, leading to misdiagnosis.<sup>6</sup> Numerous other reports of retained oxidized cellulose in other surgical sites have created diagnostic challenges.<sup>3,7-10</sup> The longest reported interval between placement of a hemostatic agent and confirmation by either FNA biopsy or surgery was 46 months.

Thus, delayed absorption should be considered for at least three years. It is important to document and confirm oxidized cellulose (Surgicel®) use on all surgical operative reports as it could carry medicolegal implications and aid in future surveillance. The clinician can use this documentation to highly suspect or confirm retained oxidized cellulose (Surgicel®) as a plausible diagnosis of a mass found in a tumor bed. While hemostatic agents are valuable surgical tools, judicious application and awareness of potential complications like foreign body reactions are paramount.

This review acknowledges inherent limitations. Firstly, the retrospective nature introduces potential confounding biases inherent in such studies. Secondly, a significant limitation lies in the lack of specific details regarding the type of oxidized cellulose product used. While our case employed Surgicel® Fibrillar, a recurring issue within the reviewed case reports is the absence of this crucial information.

## Conclusion

While oxidized cellulose (Surgicel®) offers hemostatic benefits during thyroid surgery and typically resorbs within one to two weeks, cases of delayed or incomplete resorption exist. This poses a challenge as the residual material can mimic residual thyroid tissue or tumor recurrence on imaging. To prevent unnecessary interventions like biopsies or repeat surgeries, a review of operative reports for Surgicel® usage is crucial. Furthermore, recognizing the characteristic features of Surgicel® on cytology and/or postoperative ultrasound becomes paramount for accurate diagnosis, potentially alleviating patient anxiety and avoiding unnecessary procedures.

## Lessons Learned

Though designed for resorption, residual hemostatic agents can mimic tissues or tumors on post-surgical imaging, requiring inclusion in the differential diagnosis. Careful imaging or biopsy helps differentiate lingering agents like Surgicel® from concerning tissue.

## References

- Royds J, Kieran S, Timon C. Oxidized cellulose (Surgicel) based reaction post thyroidectomy mimicking an abscess: A case report. *Int J Surg Case Rep.* 2012;3(7):338-339. doi:10.1016/j.ijscr.2012.03.034
- Haugen BR. 2015 American Thyroid Association Management Guidelines for Adult Patients with Thyroid Nodules and Differentiated Thyroid Cancer: What is new and what has changed?. *Cancer.* 2017;123(3):372-381. doi:10.1002/cncr.30360
- Hernández-Bonilla S, Rodríguez-García AM, Jiménez-Hefernan JA, et al. FNA cytology of postoperative pseudotumoral lesions induced by oxidized cellulose hemostatic agents. *Cancer Cytopathol.* 2019;127(12):765-770. doi:10.1002/cncy.22194
- Liu J, Hong W, Wu W, Ni H, Zhou M. Delayed Absorption of Oxidized Cellulose (Surgicel) in Post-Thyroidectomy Patients. *J Ultrasound Med.* 2016;35(6):1349-1351. doi:10.7863/ultra.15.08014
- Kamaya A, Gross M, Akatsu H, Jeffrey RB. Recurrence in the thyroidectomy bed: sonographic findings [published correction appears in *AJR Am J Roentgenol.* 2011 Feb;196(2):477]. *AJR Am J Roentgenol.* 2011;196(1):66-70. doi:10.2214/AJR.10.4474
- Sabel M, Stummer W. The use of local agents: Surgicel and Surgifoam. *Eur Spine J.* 2004;13 Suppl 1(Suppl 1):S97-S101. doi:10.1007/s00586-004-0735-z
- Rustagi T, Patel K, Kadrekar S, Jain A. Oxidized Cellulose (Surgicel) Causing Postoperative Cauda Equine Syndrome. *Cureus.* 2017;9(7):e1500. Published 2017 Jul 21. doi:10.7759/cureus.1500
- Sandhu GS, Elexpuru-Camiruaga JA, Buckley S. Oxidized cellulose (Surgicel) granulomata mimicking tumour recurrence. *Br J Neurosurg.* 1996;10(6):617-619. doi:10.1080/02688699646989
- Somani BK, Kasthuri RS, Shave RM, Emtage LA. Surgicel granuloma mimicking a renal tumour. *Surgery.* 2006;139(3):451. doi:10.1016/j.surg.2005.11.013
- Zhang F, Bonidie MJ, Ventrelli SM, Furlan A. Intraovarian oxidized cellulose (Surgicel) mimicking acute ovarian pathology after recent pelvic surgery. *Radiol Case Rep.* 2015;10(4):39-41. Published 2015 Sep 26. doi:10.1016/j.radcr.2015.08.002