

Catamenial Hemopneumothorax: An Unusual Presentation of Spontaneous Pneumothorax

AUTHORS:

Frank Villa Hernandez; Kyle C. Purrman; Aundrea L. Oliver, MD; Carlos J. Anciano, MD; Mark D. Iannettoni, MD, MBA; James E. Speicher, MD

CORRESPONDENCE AUTHOR:

Dr. James E. Speicher
115 Heart Dr.
East Carolina University Brody School of Medicine
Greenville, NC 27834
speicherj15@ecu.edu

AUTHOR AFFILIATIONS:

Brody School of Medicine at East Carolina University
Department of Cardiovascular Sciences
Greenville, NC 27834

Background	A catamenial pneumothorax is defined as a spontaneous and often recurrent pneumothorax with a temporal relationship to menstruation. Most commonly, the underlying pathophysiological process is the ectopic implantation of endometrial tissue (endometriosis) in the thorax. Previously thought to be a rare entity accounting for only three to six percent of pneumothoraces in otherwise healthy women, more recent data suggests that catamenial pneumothorax may account for up to 35 percent of pneumothoraces in healthy women. Presented within this case report is an example of ectopic endometrial tissue causing a recurrent hemopneumothorax in a 26-year-old female.
Summary	A 26-year-old African American female presented to the emergency department with a one-day history of sharp chest pain and a history of recurrent pneumothoraces that coincided with her menstrual cycle. A chest X ray revealed a moderate right pneumothorax. Further workup with computed tomography (CT) scan confirmed the small to moderate right pneumothorax with additional concern for a hemothorax. The patient underwent video-assisted thoracoscopic surgery (VATS) with wedge resection/blebectomy, partial pleurectomy, and mechanical pleurodesis at this time. Multiple fenestrations as well as small blue-gray nodules were noted on the surface of the diaphragm intraoperatively. Histological evaluation of the resected diaphragmatic implants revealed only benign skeletal muscle with inflammatory infiltrate; analysis of the resected lung segments showed mild emphysematous changes with focal subpleural blebs, edema, and fibrosis. The patient tolerated the procedure well and was discharged on postoperative day two. In subsequent follow-up visits, the patient noted no recurrence of symptoms or of pneumothorax.
Conclusion	In this patient with recurrent spontaneous pneumothoraces around onset of the menstrual cycle, endometriosis with concomitant diaphragmatic fenestrations is a likely cause. The diagnosis of this entity does not depend on biopsy and endometrial tissue is not always identified on pathologic examination, as was the case in our experience. Effective treatment of this problem includes VATS as a diagnostic and therapeutic modality with blebectomy and pleurodesis coupled with 6–12 months of hormonal suppression therapy to prevent recurrence of symptoms. Early clinical follow-up with subsequent surveillance is also recommended as recurrence rates are high despite appropriate surgical intervention. A high degree of clinical suspicion is necessary in these patients to avoid the morbidity associated with this problem.
Keywords	Catamenial pneumothorax, recurrent pneumothorax, endometriosis

DISCLOSURE:

The authors have no conflicts of interest to disclose.

To Cite: Villa Hernandez F, Purrman KC, Oliver AL, Anciano CJ, Iannettoni MD, Speicher JE. Catamenial Hemopneumothorax: An Unusual Presentation of Spontaneous Pneumothorax. *ACS Case Reviews in Surgery*. 2018;2(2):36-41.

Case Description

Catamenial pneumothorax is defined as a spontaneous and often recurrent pneumothorax in women of reproductive age that has a temporal relationship with menstruation.¹ It most often occurs secondary to the ectopic implantation of endometrial tissue within the thorax. It was previously thought to be a rare entity, as past data showed this phenomenon accounted for only three to six percent of spontaneous pneumothoraces in otherwise healthy women.¹ However, more recent data suggests that catamenial pneumothorax may have a higher incidence, with rates accounting for as many as 25 to 35 percent of spontaneous pneumothoraces in healthy women.^{2,3} We present the case of a recurrent hemopneumothorax, thought to be related to ectopic endometriosis, in an otherwise healthy, young female.

The patient is a 26-year-old African American female who presented to the emergency department with a one-day history of chest pain and shortness of breath. The chest pain was right-sided, exacerbated by deep inspiration and described as being a 3/10 in intensity with a “sharp” character. The patient had started her menses that same day and was having diffuse, cramping abdominal pain that was worse than previous menstrual cycles. A chest X ray in the emergency department showed a small right-sided pneumothorax with a trace right pleural effusion (Figure 1).

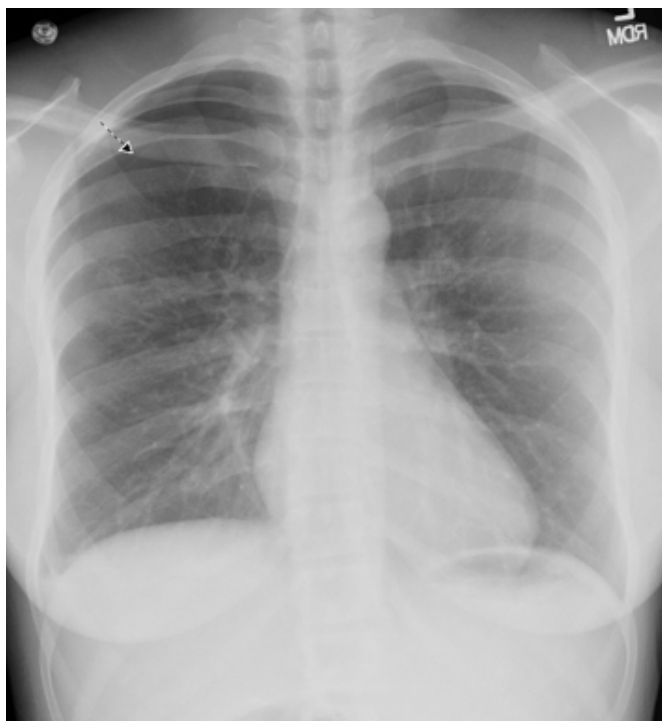


Figure 1. Presenting chest X ray showing small right pneumothorax.

The patient’s medical history consisted of gastroesophageal reflux disease and recurrent pneumothorax (two in the past year, both right-sided and associated with onset of menses) that resolved with administration of oxygen in the emergency department. Her gynecologic history was significant for dysmenorrhea and spontaneous vaginal delivery nine years ago. Of note, she had no known diagnosis of pelvic endometriosis. In addition, she had no consistent pulmonary care and pulmonary function tests had never been performed. We did not perform these tests during her acute presentation as the presence of a pneumothorax would have rendered them inaccurate.

Physical examination at the time of presentation showed diffuse abdominal tenderness and bleeding in the vagina but was otherwise unremarkable. Her cardiac and lung exam were normal. The patient was an active smoker and had a 10-pack-year history of smoking. No abnormalities were identified on laboratory studies. Computed tomography (CT) scan of the chest without contrast showed a small-to-moderate right pneumothorax and a small amount of pleural fluid in the right pleural base that was concerning for small hemothorax based on Hounsfield units of 53.5 (Figure 2).

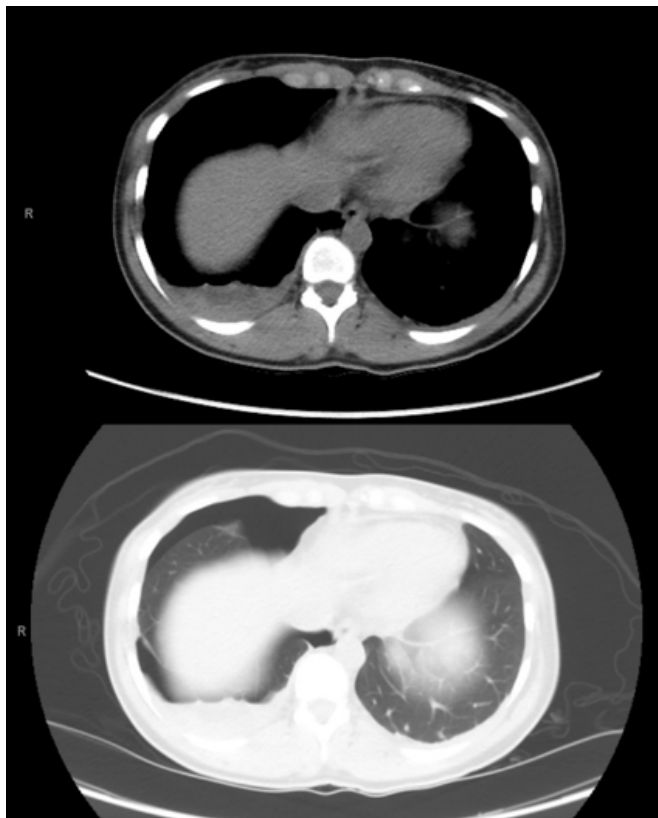

Figure 2. Presenting CT scan showing small right sided effusion and pneumothorax.

No radiographic abnormalities were found in the left chest. Given the patient's clinical picture of recurrent pneumothorax during her menstrual cycle, in addition to her imaging studies, the differential diagnosis included catamenial pneumothorax as well as idiopathic spontaneous pneumothorax. Because of the concern for possible catamenial pneumothorax and the recurrent nature of her disease, she was scheduled for right video-assisted thoracoscopic surgery (VATS) with wedge resection/blebectomy, partial pleurectomy, and mechanical pleurodesis. Her pneumothorax was small, and she was oxygenating well, so a thoracostomy tube was not placed at the time of initial presentation.

After induction of general anesthesia and intubation with a double lumen endotracheal tube, the patient was prepped and draped sterilely. The right lung was deflated and a 1-cm incision was made in the posterior axillary line in the seventh intercostal space for the thoracoscopic camera. Working incisions were made in the fifth intercostal space anteriorly and posteriorly. Adhesions were noted at the apex of the lung. Because these adhesions could represent scar tissue from previous parenchymal blebs in the area, it was elected to resect this area of lung. All adhesions were taken down sharply with electrocautery. The apex was then grasped and amputated with multiple firings of an endoscopic stapler, taking care to make sure all bullous and scar tissue was removed (Figure 3).

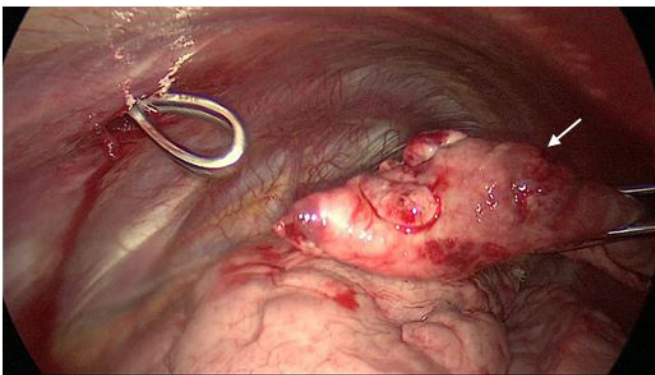


Figure 3. Representative figure showing the completely resected specimen, with bullous tissue at the superior aspect.

The diaphragm was then examined and was noted to have several small subcentimeter blue nodules on the surface. Two of these nodules were removed and sent for pathology, the others appeared to be too small to remove. Additionally, it was noted that there were several small fenestrations in the diaphragm. The largest of these was repaired with a horizontal mattress suture, and the others were so small that they were thought to be of no clinical significance. No other abnormal tissue deposits were noticed on examination of the remaining parietal pleura and lung parenchyma. A partial pleurectomy near the apex was then performed by scoring the pleura over the surface of the fifth rib and removing the pleura superior to this line circumferentially (Figure 4).

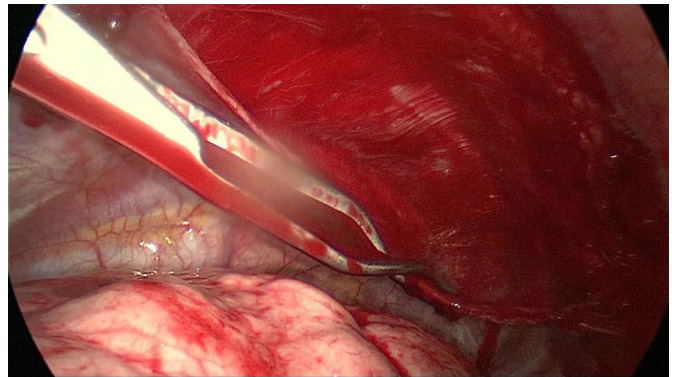


Figure 4. Representative figure showing partial pleurectomy in process.

Mechanical pleurodesis was performed with a Bovie scratch pad over the remainder of the chest wall and diaphragm (Figure 5).

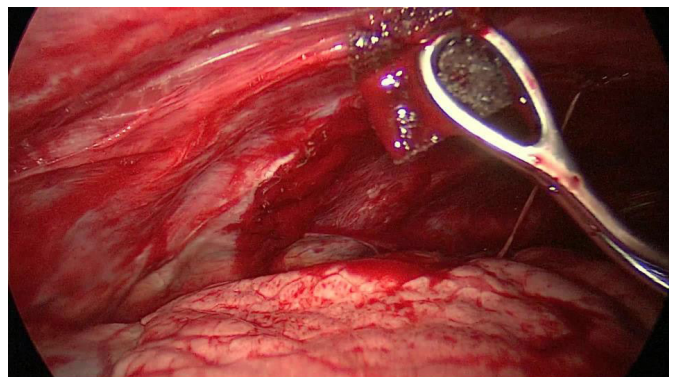


Figure 5. Representative figure showing mechanical pleurodesis with a Bovie scratch pad.

This technique of partial pleurectomy above the fifth rib with mechanical abrasion below is the preferred technique of the author in young patients with multiple recurrent episodes and risk factors for further recurrence, and it is well documented in the literature as a standard method of treatment.¹² A 28-French chest tube was placed apically, and the lung was observed to re-inflate well. The chest tube was secured in place and the incisions were closed in layers.

Histological evaluation of the resected diaphragmatic implants revealed only benign skeletal muscle with inflammatory infiltrate; analysis of the resected lung segments showed mild emphysematous changes with focal subpleural blebs, edema, and fibrosis. The patient's postoperative course was uncomplicated. She was discharged from the hospital on postoperative day two. At follow-up, she had complete expansion of her lung on chest X ray (Figure 6), and she has not experienced any further episodes of spontaneous pneumothorax since operation.

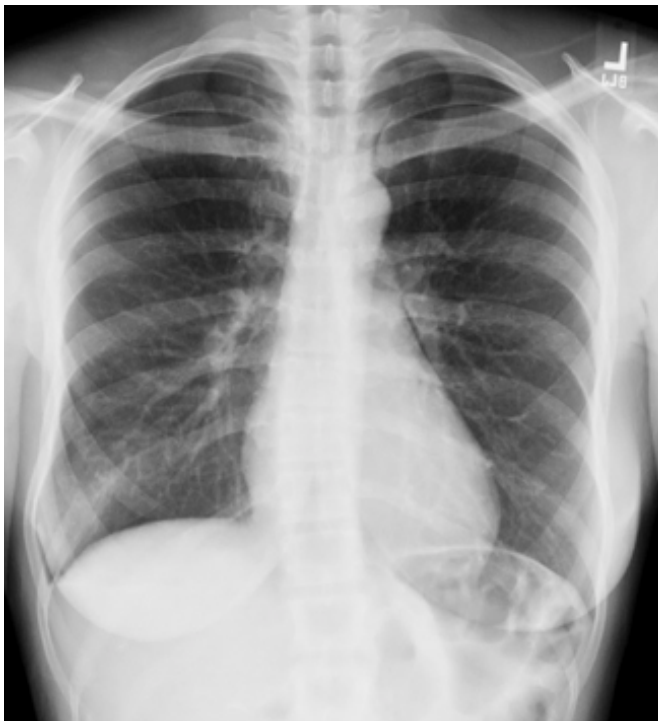

Figure 6. Postoperative follow-up chest X ray showing complete expansion of the right lung.

Discussion

Although not fully understood, it is thought that the most common underlying pathophysiological process of catamenial pneumothorax is endometriosis (the presence of endometrial glands and stroma outside the confines of the uterine cavity). While endometriosis most commonly manifests itself in the pelvic cul-de-sac, causing a variety of pelvic pain and infertility syndromes, it can also appear within the thoracic cavity as one of four manifestations: catamenial hemoptysis, endometrial stromal nodules in lung parenchyma or visceral pleura, and catamenial hemothorax.⁴ The exact mechanism of how ectopic endometrial tissue reaches the thorax is still widely debated, but there are several competing theories. The first was described in 1927 by Sampson; it involves retrograde menstruation with implantation in the peritoneum followed by transdiaphragmatic migration through fenestrations produced by endometriosis.⁴ The second implicates metastatic spread of endometrial tissue through the venous or lymphatic system to implant elsewhere in the body.^{2,4} The third involves coelomic metaplasia of undifferentiated stem cells into endometrial tissue since both the abdominal and thoracic cavity are covered by the coelomic membrane.⁴ Furthermore, the pathogenesis of catamenial pneumothorax is also unclear, one explanation is that similar to its intra-uterine counterpart, ectopic endometrial tissue undergoes the phases of the menstrual cycle and may release air or blood into the pleural space, causing a recurrent spontaneous hemothorax or pneumothorax. Other explanations include spontaneous rupture of blebs, alveolar rupture due to prostaglandin-induced bronchiolar constriction, and the absence of a cervical mucous plug allowing the passage of air from the genital tract through diaphragmatic fenestrations.⁵

While extremely variable, the most common clinical presentation of catamenial pneumothorax is recurrent pleuritic chest pain, shortness of breath, fatigue, and cough that has a characteristic temporal relationship with the onset of menstruation.⁶ It has been widely accepted that spontaneous pneumothorax occurs within the window of 24 hours before to 72 hours after the beginning of menstruation.² The endometrial implants most commonly present in the right hemithorax (87.5 to 100 percent in reported case series) but can also be left-sided or bilateral in nature.⁶ Catamenial pneumothorax can present in the setting of existing pelvic endometriosis, although there is varying data suggesting anywhere from 18.8 percent to 51 percent of patients with catamenial pneumothorax have comorbid pelvic endometriosis.^{6,7}

Diagnosis of catamenial pneumothorax is typically delayed due to a lack of clinical suspicion for this process as the cause of pneumothorax. As such, this etiology must be suspected in women of reproductive age presenting with the characteristic clinical picture. Definitive diagnosis can be made by high-resolution CT scan which may show pleural or parenchymal nodules, pneumothorax, pleural effusions, cavitation, or bullae.⁶ However, more commonly, the endometrial implants are found incidentally on thoroscopic evaluation of the patient with pneumothorax. Biopsy of implants found in the chest cavity is not essential to make the diagnosis as histologic confirmation of endometrial glands and stroma varies across reports, ranging from 53 to 75 percent in clinically-suspected cases of catamenial pneumothorax.^{2,3,8} As further evidence of the inconsistent findings of endometrial tissue within the thorax, a more recent report from 2016 revealed the lack of histologic confirmation in all of their clinically diagnosed cases despite the concurrent presence of morphologic features (nodular deposits and diaphragmatic fenestrations) on surgical examination.⁹

In the case of our patient, given her active smoking history and histologic bleb findings consistent with mild emphysematous changes, an argument could be constructed for parenchymal lung disease as the source of her pneumothorax. However, catamenial pneumothorax and apical bleb disease are not mutually exclusive processes. In a paper by Alifano and colleagues, 50 percent of patients with clinically diagnosed, morphologically supported, and histologically confirmed catamenial pneumothorax had concomitant apical bleb disease revealing bullous dystrophy without signs of pulmonary or visceral pleural endometriosis.⁵ Therefore, we postulate that even in the presence of underlying lung pathology, the diagnosis of catamenial pneumothorax is contingent upon clinical suspicion prompted by the temporal relationship of spontaneous pneumothorax to menstruation and is supported by identification of gross morphologic findings.

Both surgical approaches and hormonal therapy used in combination, or as separate entities, are employed in the treatment of catamenial pneumothorax. VATS is typically performed as both a diagnostic and therapeutic modality. A fiberoptic camera is used to visualize the thoracic cavity, lung parenchyma, and diaphragmatic surface to look for the characteristic brown/blue endometrial implants or parenchymal blebs. Removal of blebs and mechanical

pleurodesis are routinely performed in order to prevent recurrence of the pneumothorax. Greater than 50 percent of patients will also have small perforations or fenestrations of the diaphragm. These may be sewn closed with or without mesh patch or left alone if very small.¹⁰ Hormonal suppressive therapy is typically employed for 6 to 12 months following surgery in order to suppress ovulation and aid in preventing recurrence. Any treatment should also include smoking cessation as active smoking is associated with spontaneous pneumothorax in the absence of parenchymal lung disease, and cessation has been shown to reduce recurrence rates.¹¹ However, despite a multifaceted approach to treatment, recurrence rates remain high, up to 32 percent in some reports with a mean follow-up time of two years.²

Conclusion

Even given the breadth of modern medical knowledge and the current climate in medicine, catamenial pneumothorax remains a poorly-understood and under-recognized entity that carries significant morbidity in women of reproductive age. Clinical suspicion must be raised by the characteristic symptomatology of recurrent pneumothorax with temporal relationship to menstruation. Diagnosis is made by obtaining a high-resolution CT scan and observing the characteristic lesions in the thorax. Optimal management involves VATS with surgical blebectomy and pleurodesis along with 6 to 12 months of hormonal suppression to prevent recurrence of pneumothorax. Early recognition and prompt management of this phenomenon will prevent women from enduring the pain of recurrent pneumothorax without proper diagnosis and management of the underlying etiology.

Lessons Learned

Although a poorly-understood and under-recognized entity, catamenial pneumothorax carries significant morbidity in women of reproductive age. Clinical suspicion must be raised by the characteristic symptomatology of recurrent pneumothorax with temporal relationship to menstruation. While no clear recommendations exist in the literature to dictate specific follow up intervals, early clinical follow up with subsequent surveillance of these patients is recommended due to high recurrence rates.

References

1. Blanco S, Hernando F, Gomez A, et al. Catamenial pneumothorax caused by diaphragmatic endometriosis. *J Thorac Cardiovasc Surg.* 1998;116:179-180.
2. Alifano M, Jablonski C, Kadiri H, et al. Catamenial and Noncatamenial, Endometriosis-related or Nonendometriosis-related Pneumothorax Referred for Surgery. *Am J Respir Crit Care Med.* 2007;176:1048-1053.
3. Legras A, Mansuet-Lupo A, Rousset-Jablonski C, et al. Pneumothorax in Women of Child-Bearing Age An Update Classification Based on Clinical and Pathologic Findings. *Chest.* 2014;145(2):354-360.
4. Harkki P, Jokinen J, Salo J, Sihvo E. Menstruation-related spontaneous pneumothorax and diaphragmatic endometriosis. *Acta Obstet et Gynecol.* 2010;89:1192-1196.
5. Alifano M, Roth T, Broet S, et al. Catamenial Pneumothorax* A Prospective Study. *Chest.* 2003;124:1004-1008.
6. Visouli AN, Zarogoulidis K, Kougioumtzi I, et al. Catamenial pneumothorax. *J Thorac Dis.* 2014; Oct:S448-60.
7. Korom S, Canyurt H, Missbach M. Catamenial pneumothorax revisited: clinical approach and systematic review of the literature. *J Thorac Cardiovasc Surg.* 2004;128:502-508.
8. Rousset-Jablonski C, Alifano M, Plu-Bureau G, et al. Catamenial pneumothorax and endometriosis-related pneumothorax: clinical features and risk factors. *Hum Reprod.* 2011;26:2322-9.
9. Mehta CK, Stanifer BP, Fore-Kosterski S, et al. Primary Spontaneous Pneumothorax in Menstruating Women Has High Recurrence. *Ann Thorac Surg.* 2016;102(4):1125-1130.
10. Bricelj K, Srpac M, Razem A, Snoj Z. Catamenial pneumothorax since introduction of video-assisted thoracoscopic surgery: A systematic review. *Wien Klin Wochenschr.* 2017 Jul 31.
11. Sadikot RT, Greene T, Meadows K, Arnold AG. Recurrence of primary spontaneous pneumothorax. *Thorax.* 1997;52:805-809.
12. Fernandes P, Lareiro S, Monteiro JP, et al. Surgical management of primary spontaneous pneumothorax: 11 years experience. *Rev Port Cir Cardiothorac Vasc.* 2016 Jul-Dec;23:119-24.