

# Radio-Guided Robotic Parathyroidectomy for Mediastinal Parathyroid Gland

**AUTHORS:**

Shelby L. Bergstresser, Benjamin Wei, MD;  
Pradeep G. Bhambhani, MD; and Herbert  
Chen, MD

**CORRESPONDENCE AUTHOR:**

Dr. Herbert Chen  
UAB Department of Surgery  
1808 7th Avenue South, Suite 502  
Boshell Diabetes Building  
Birmingham, AL 35233  
Phone: (205) 934-3333  
Email: herbchen@uab.edu

**AUTHOR AFFILIATIONS:**

Department of Surgery  
University of Alabama at Birmingham  
Birmingham, AL 35233

<b>Background</b>	A 58-year-old male presented with persistent primary hyperparathyroidism (PHPT) several months after undergoing hemithyroidectomy with cervical exploration. Imaging demonstrated ectopic mediastinal parathyroid gland. After evaluation by endocrine and thoracic surgery teams, a decision was made to use radio-guided robotic surgery to facilitate removal of the ectopic glands.
<b>Summary</b>	Unsuccessful localization of ectopic glands during primary surgery can lead to persistent PHPT and predispose patients to complications from longstanding hypercalcemia. Current approaches to removing ectopic parathyroid glands include sternotomy and video-assisted thoracic surgery (VATS). Although these methods have high success rates in removal of ectopic glands, they have well-documented risks and drawbacks. Robotic surgery has been used for ectopic parathyroid gland removal, but there are limited reports available on its use in cases of ectopic glands. We describe a case utilizing radio-guided robotic surgery for successful removal of an ectopic mediastinal parathyroid gland.
<b>Conclusion</b>	Radio-guided robotic parathyroidectomy can be employed as an additional approach to ectopic parathyroid gland removal.
<b>Keywords</b>	Primary hyperparathyroidism, PHPT, parathyroid, parathyroidectomy, ectopic, robotic, radiotherapy, hyperparathyroidism

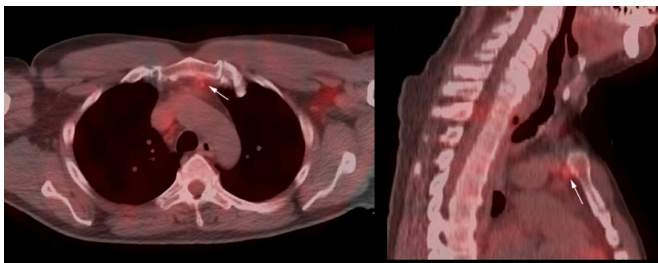
**DISCLOSURE:**

The authors have no conflicts of interest to disclose.

**To Cite:** Bergstresser SL, Wei B, Bhambhani PG, Chen H. Radio-Guided Robotic Parathyroidectomy for Mediastinal Parathyroid Gland. *ACS Case Reviews in Surgery*. 2019;2(3):1-4.

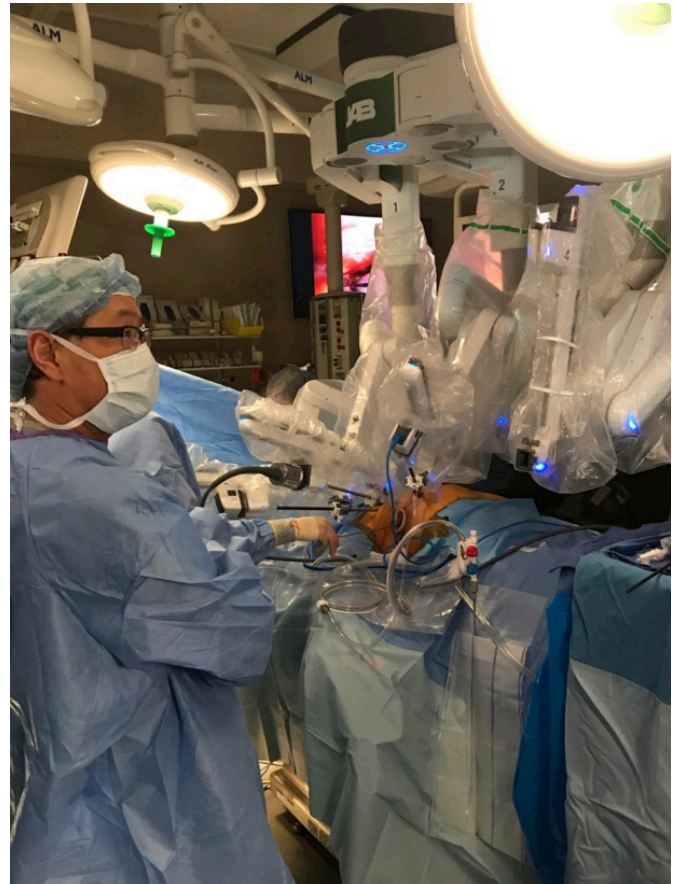
## Case Description

A 58-year-old male initially presented to his primary care provider with a six-month history of fatigue, joint pain, and depression. Labs at that time showed a calcium of 10.6 mg/dL (8.4 mg/dL–10.4 mg/dL), parathyroid hormone level of 92 pg/mL (12 pg/mL–88 pg/mL), and normal vitamin D levels. He was then referred to a surgeon at an outside hospital who diagnosed primary hyperparathyroidism and ordered imaging. Ultrasound demonstrated small bilateral thyroid nodules with no evidence of parathyroid adenoma, and Sestamibi scan was non-localizing. Due to negative localization studies, a full cervical exploration with right thyroidectomy was scheduled, and the patient underwent the procedure in September 2017. No intraoperative parathyroid hormone monitoring was performed. Pathology reports from the operation showed no identifiable parathyroid tissue in any samples submitted for analysis. Postoperatively the patient continued to remain symptomatic and subsequently presented to the endocrine surgery clinic at the University of Alabama at Birmingham. Labs upon presentation showed calcium 11.5 mg/dL (8.4 mg/dL–10.4 mg/dL), parathyroid hormone 50.5 pg/mL (12 pg/mL–88 pg/mL), and vitamin D 23 ng/mL (20 ng/mL–100 ng/mL). Imaging with Tc-99m Sestamibi SPECT imaging demonstrated a 6 x 5 x 12 mm nodule behind superior manubrium and left of midline suspicious for ectopic parathyroid lesion (Figure 1). A preoperative diagnosis of PHPT due to a missed mediastinal parathyroid adenoma was given. The patient was then seen by thoracic surgery, who agreed with the diagnosis and scheduled a joint radio-guided robotic parathyroid resection with intraoperative parathyroid hormone monitoring.



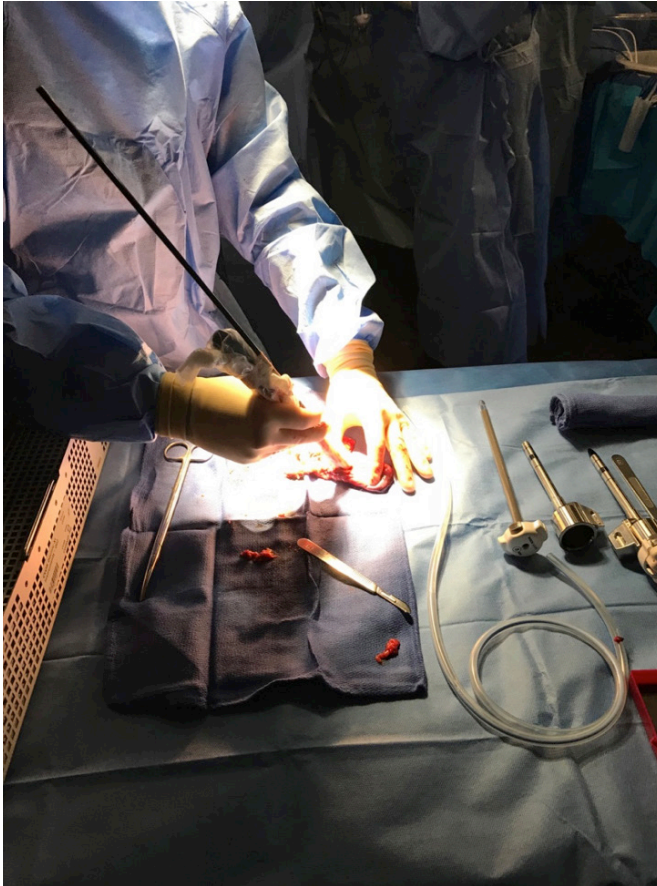**Figure 1.** SPECT CT image showing Sestamibi avid 6 x 5 x 12 mm nodule behind the superior manubrium

Prior to procedure, the patient was injected with 10 mCi TC-99m Sestamibi. The preoperative parathyroid hormone level was 80 pg/mL. The right and central chest were prepped and draped in a sterile fashion. The robot was docked (Figure 2).



**Figure 2.** da Vinci Robot setup

It was difficult to visualize any abnormalities that corresponded with the CT and Sestamibi scan findings. The radio-guided approach was then utilized to assist in finding the ectopic parathyroid tissue. The thymus was identified. The gamma probe was placed through the chest wall, and we determined a background level of 147 using the lung. The chest was scanned with the gamma probe and counts higher than the background were found in the thymus; therefore, the thymus was resected. The ex vivo count of resected ectopic tissue was 62 (Figure 3).



**Figure 3.** Gamma probe being used to determine ex-vivo radioactive counts of removed parathyroid tissue

For localization of ectopic tissue to be considered successful, the ex-vivo count of excised tissue should be 20 percent or more of the initial background count. In our case, the background count was 147, and the ectopic tissue had a count of 62 (greater than 20 percent of our background), indicating successful localization and removal of tissue. Intraoperative parathyroid hormone levels were then sent at 5, 10, and 15 minutes postexcision and found to be 22, 15, and 13 pg/mL, respectively, indicating surgical cure. Hemostasis was confirmed and a 24 French rigid chest tube was placed. The patient stayed overnight and was discharged home the following day. The patient followed up in clinic one month postoperatively. Labs showed calcium 9.6 mg/dL and PTH of 23.4 pg/mL, and he reported resolution of symptoms.

## Discussion

Although most cases of PHPT are due to a single adenoma and amenable to established cervical approaches, 6 to 30 percent of cases can be attributed to ectopic mediastinal glands that are not accessible through standard methods due to their location in the thorax.<sup>1</sup> Sternotomy was the initial approach to these mediastinal glands, and although highly effective, incurred longer hospital stays and increased risks. An alternative approach utilized for removal of ectopic glands is VATS. This method has demonstrated successful outcomes, shorter hospital stays, and fewer complications compared to sternotomy.<sup>1,2</sup> Since the introduction of the da Vinci robot, surgeons have also begun using this technique for parathyroidectomy. Although there is extensive literature regarding various approaches for cervical parathyroidectomy using the robot, there are limited reports on the use of the robot for mediastinal parathyroid removal.<sup>3</sup> In this case report, we detailed the use of radio-guided approach with robot-assisted surgery for removal of an ectopic mediastinal parathyroid gland. To our knowledge, this is the first reported case utilizing all of these technologies.

Both VATS and robotic approaches have been detailed for conventional parathyroidectomy. Limitations of thoroscopic approaches include two-dimensional viewing, restricted degree of instrumentation mobility, and difficulty with field alignment and stabilization of the camera. In comparison, the robotic approach allows for increased surgeon dexterity, a three-dimensional view of the surgical field, and better camera-field-instrumentation alignment.<sup>3</sup> There is only one report describing the use of the robotic approach for ectopic parathyroid glands.<sup>4</sup> Our study utilizes the same approach; however, we also implemented use of the gamma probe to help guide localization during surgery, which has not been previously described. Use of radio-guided parathyroidectomy eliminates the need for frozen sections and helps localize difficult to find glands.<sup>1</sup> Radio-guided techniques have been shown to be highly effective for resection of parathyroid glands in the neck.<sup>5,6</sup> This technique can be particularly helpful in the case of ectopic glands, where dissection may be complicated due to gland location in an uncommon site.

## Conclusion

Ectopic mediastinal parathyroid adenomas are not an uncommon cause of PHPT. We present a case of a 58-year-old man with mediastinal parathyroid gland and PHPT who was treated surgically using radio-guided robotic parathyroidectomy. This demonstrates a novel approach using radio-guided technology and the robot to identify and remove ectopic parathyroid glands.

## Lessons Learned

PHPT due to ectopic mediastinal glands occasionally requires an approach from the chest rather than the neck. Gland location in an unfamiliar area can complicate localization during the procedure. Radio-guided robotic parathyroidectomy allows for easier localization and maneuvering during the procedure.

## References

1. Weigel TL, Murphy J, Kabbani L, Ibele A, Chen H. Radio-guided thoracoscopic mediastinal parathyroidectomy with intraoperative parathyroid hormone testing. *Ann Thorac Surg.* 2005;80(4):1262-1265.
2. Fama F, Berry MG, Linard C, Gioffre' Florio M, Metois D. Successful unilateral thoracoscopy for bilateral ectopic mediastinal parathyroidectomy. *Thorac Cardiovasc Surg.* 2010;58(3):187-189.
3. Brunaud L, Li Z, Van Den Heede K, Cuny T, Van Slycke S. Endoscopic and robotic parathyroidectomy in patients with primary hyperparathyroidism. *Gland Surgery.* 2016;5(3):352-360.
4. Ismail M, Maza S, Swierzy M, et al. Resection of ectopic mediastinal parathyroid glands with the da Vinci robotic system. *Br J Surg.* 2010;97(3):337-343.
5. Chen H, Mack E, Starling JR. A comprehensive evaluation of perioperative adjuncts during minimally invasive parathyroidectomy: which is most reliable? *Ann Surg.* 2005;242(3):375-380; discussion 380-373.
6. Chen H, Mack E, Starling JR. Radio-guided Parathyroidectomy Is Equally Effective for Both Adenomatous and Hyperplastic Glands. *Ann Surg.* 2003;238(3):332-338.