

Two Cases of Ogilvie Syndrome Presenting after Stroke

AUTHORS:

Sarah M. Kling, MD; and Scott D. Goldstein, MD,
FACS, ASCRS

CORRESPONDENCE AUTHOR:

Dr. Scott D. Goldstein
Department of Surgery
Division of Colon and Rectal Surgery
Thomas Jefferson University
1100 Walnut Street
Suite 500
Philadelphia, PA 19107
Phone: (215) 570-1464
Email: scott.goldstein@jefferson.edu

AUTHOR AFFILIATIONS:

Thomas Jefferson University
Sidney Kimmel Medical College
Philadelphia, PA 19107

Background	<p>In the first presented case, a 78-year-old woman presented with abdominal pain, nausea, vomiting, and no bowel movements following a hemorrhagic stroke. Computed tomography (CT) imaging of her abdomen revealed colonic dilatation; however, there was no identifiable mechanical obstruction, nor was there fecal impaction on rectal exam. Thus, the diagnosis of Ogilvie syndrome was made. She was treated with two courses of neostigmine boluses, which both failed to relieve the pseudo-obstruction. The patient was eventually treated with colonoscopic decompression, which led to the resolution of her symptoms and return of bowel function.</p> <p>In the second presented case, a 66-year-old man presented with severe abdominal distension following a stroke. Abdominal X rays revealed colonic and small bowel dilatation. Flexible sigmoidoscopy revealed no identifiable mechanical obstruction. Thus, the diagnosis of Ogilvie syndrome was made. He was treated with two courses of neostigmine boluses, which both failed to relieve the pseudo-obstruction. The patient was eventually treated with colonoscopic decompression, and this led to the resolution of his symptoms and return of bowel function.</p>
Summary	<p>These rare case reports involve two patients who developed Ogilvie syndrome after a stroke. Ogilvie syndrome often presents with nausea, vomiting, and abdominal pain without detectable mechanical obstruction. Ogilvie syndrome classically develops secondary to retroperitoneal manipulation. Ogilvie syndrome has been seen following stroke; however, it is one of the least common causes. Stroke is thought to cause Ogilvie syndrome via autonomic dysfunction of the parasympathetic nervous system. This causes decreased bowel motility leading to fecal stasis and intestinal dilatation.</p>
Conclusion	<p>These cases suggest that perhaps Ogilvie syndrome due to stroke needs to be treated differently than cases secondary to other causes. Due to the inherent autonomic dysfunction caused by stroke leading to associated development of Ogilvie Syndrome, standard pharmaceutical management with a neostigmine bolus does not seem to be an effective first-line option. Other treatment options include neostigmine continuous infusion, longer acting acetylcholinesterase inhibitors, alternative receptor agonists, or colonoscopic decompression.</p>
Keywords	<p>Ogilvie syndrome; pseudo-obstruction; autonomic dysfunction; neostigmine; colonoscopic decompression; stroke</p>

DISCLOSURE:

The authors have no conflicts of interest to disclose.

MEETING PRESENTATION:

American Society of Colon and Rectal Surgery
Seattle, WA
June 2017

To Cite: Kling SM, Goldstein SD. Two Cases of Ogilvie Syndrome Presenting after Stroke. *ACS Case Reviews in Surgery*. 2019;2(3):29-32.

Introduction

Ogilvie Syndrome, or intestinal pseudo-obstruction, often presents with nausea, vomiting, and abdominal pain, but without detectable mechanical obstruction. Ogilvie syndrome is classically secondary to retroperitoneal manipulation. Ogilvie syndrome has been seen following stroke, thought to be due to autonomic dysfunction of the parasympathetic nervous system. The autonomic dysfunction causes decreased motility of the bowel, leading to fecal stasis and intestinal dilatation. Herein, two cases of Ogilvie syndrome presenting after stroke are detailed. In each of these cases, mechanical obstruction was ruled out early on.

Case Description

Case 1

A 78-year-old African American woman (Patient 1) presented to an outside hospital with acute hemorrhagic stroke in the left frontal and right parietal lobes. She had presented with sudden onset of expressive aphasia and right-sided hemiplegia. She had no past medical history, previous surgeries, allergies, was not on medication, and had no history of alcohol, tobacco or drug use.

The patient was eventually started on total parenteral nutrition due to inability to ingest anything by mouth. Computed tomography (CT) of the abdomen and pelvis revealed colonic distension with no evidence of mechanical obstruction (Figure 1). The patient then underwent a flexible sigmoidoscopy that revealed no obstructing mass and resulted in removal of 4 L of stool. By this time, she had numerous rectal tubes placed without resolution.

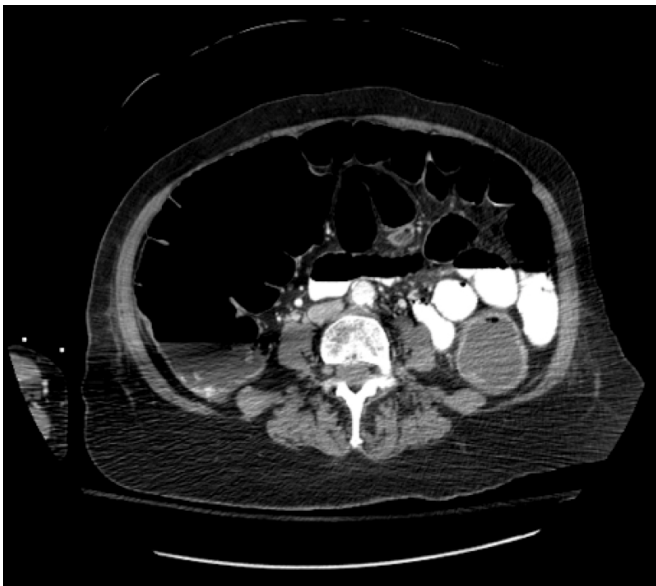


Figure 1. CT scan of Patient 1 revealing colonic distension with no evidence of mechanical obstruction

She was transferred to our hospital on the 28th day after her stroke with worsening abdominal distension and discomfort due to colonic ileus without resolution. Her last bowel movement was prior to transfer. She continued to have flatus and denied nausea or vomiting. Her abdomen was soft, severely distended and diffusely tender to palpation. There was no fecal impaction on digital rectal exam.

Imaging showed increased colonic dilatation. A neostigmine bolus was given with no improvement. She had continued pain and distention with no flatus or bowel movements. Simethicone was started to prevent gaseous distension. Two days after the initial dose of neostigmine, a second dose was given with no improvement.

Colonoscopic decompression was performed at this point. The day after, she had a soft abdomen with no distension or tenderness to palpation and was better tolerating a full liquid diet. A couple of days later she had not yet had a bowel movement, oral intake remained minimal, and her abdominal distension worsened. The following week, she began to have flatus and bowel movements.

Case 2

A 66-year-old man (Patient 2) presented to an outside hospital with a stroke with right internal carotid artery occlusion at the neck and up to the middle cerebral artery. He had presented in atrial fibrillation with rapid ventricular rhythm along with dysarthria and left-sided hemiplegia, but was outside the window for tissue plasminogen activator. He had a history of active alcohol abuse with daily consumption and tobacco use. He was not taking home medications and had no allergies. He was transferred to our hospital, where he underwent mechanical thrombectomy and right internal carotid artery stent placement.

The patient was intubated due to increased work of breathing, and tube feeds were begun through a Dobhoff tube. Throughout this time, daily abdominal exams and X rays revealed gradually worsening abdominal distension with marked colonic and small bowel dilatation (Figure 2). The Dobhoff tube was replaced by a nasogastric tube for intestinal decompression. A CT scan and flexible sigmoidoscopy performed 14 days after his stroke showed no mechanical obstruction, consistent with a diagnosis of Ogilvie syndrome. Over time, the patient had numerous rectal tubes placed without resolution.

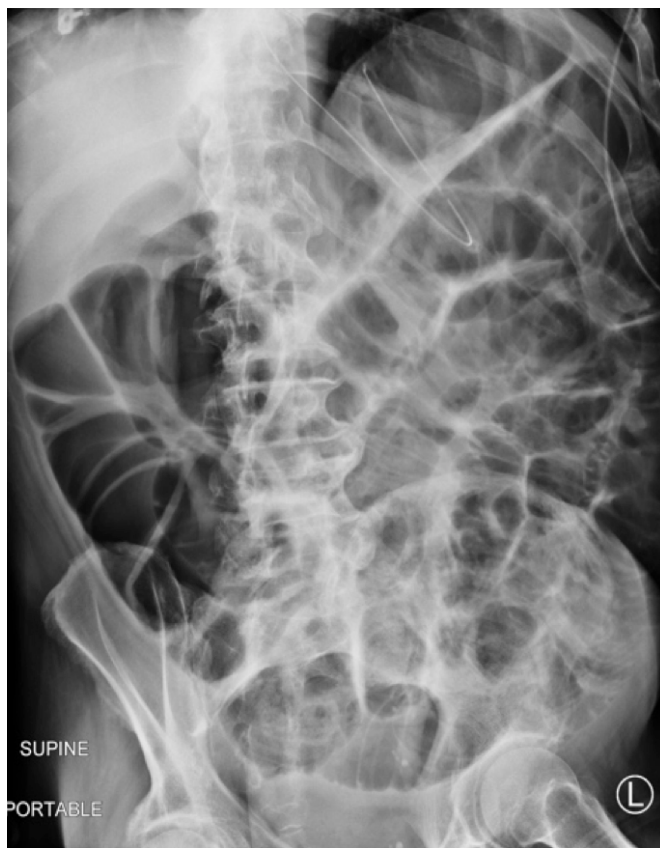

Figure 2. Abdominal X ray of Patient 2 revealing colonic and small bowel dilatation

The patient continued to have persistent colon distension and received a bolus of neostigmine. Two days later, an abdominal X ray showed mild decrease in colonic dilatation. Later that day, a second dose of neostigmine was given with no improvement.

Then colonoscopic decompression was attempted that revealed probable ischemic colitis at the splenic flexure, and this procedure was subsequently terminated due to concern for colonic perforation. The following CT of the abdomen and pelvis revealed no signs of perforation. The next day, abdominal X-ray imaging noted decreased colonic dilatation.

Discussion

The occurrence of Ogilvie syndrome following a stroke is thought to be secondary to autonomic dysfunction,¹ likely with excess sympathetic stimulation and parasympathetic inhibition.² After supportive care, slow intravenous injection of neostigmine is currently the standard of care for treatment of Ogilvie syndrome in new onset and refractory cases.^{2,3} Neostigmine is a short-acting acetylcholinesterase

inhibitor that prevents the degradation of acetylcholine. Thus neostigmine increases parasympathetic activity leading to muscular contraction of the bowel wall by increasing the availability of acetylcholine at the neuromuscular junction for brief periods of time. Patients 1 and 2 both failed multiple neostigmine boluses without trial of other pharmaceutical options. This begs a question: is neostigmine the appropriate initial treatment for patients with Ogilvie syndrome following stroke?

For cases of pseudo-obstruction that are refractory to boluses of neostigmine, there has been evidence for success using a continuous infusion of neostigmine. It is thought that the continuous infusion allows for the action of neostigmine to persist for longer periods of time to cause sustained stimulation of the bowel to have return of function.² However, due to the side effects of bronchospasm and bradycardia, continuous infusion of neostigmine should be administered under telemetry in an intensive care unit.²

Alternatively, pyridostigmine has been proven to be effective in treating specifically recurrent cases of pseudo-obstruction.⁴ Pyridostigmine is a long-acting acetylcholinesterase inhibitor; it is proposed that pyridostigmine is effective in recurrent cases of Ogilvie syndrome because it prolongs the action of acetylcholine even further. Pyridostigmine was shown to be effective in patients with primarily colonic involvement as well as those with additional small bowel dilatation.⁴

In addition, 5-Hydroxytryptamine (5-HT) receptor 4 agonists such as prucalopride may be efficacious for patients with Ogilvie syndrome. This medication acts by improving peristalsis and causing faster colonic transit leading to more frequent bowel movements.⁵ In the bowel, 5-HT acts on afferent fibers of the vagus nerve, causing parasympathetic stimulation. Prucalopride has been shown to relieve symptoms of pseudo-obstruction such as bloating, nausea, vomiting, and abdominal pain.⁵ Prucalopride was observed to be well-tolerated with no significant side effects reported.⁵

Other literature suggests that the invasive method of colonoscopy for colonic decompression is more successful as the initial treatment for pseudo-obstruction than the current standard of neostigmine. It has been shown that one colonoscopy has greater efficacy requiring no further treatments than even two courses of neostigmine.⁶ It was found that neostigmine administration prior to colonoscopy did not affect clinical outcomes when compared to no neostig-

mine given before decompression.⁶ Colonoscopy was more successful as an initial treatment and in decreasing the need for a second treatment method.⁷ Perforation is a risk associated with colonoscopic decompression because air insufflation in an already distended colon from large stool volume can cause further distention and increased intra-luminal pressure.⁷ However, early decompression can lead to prevention of the development of ischemia and perforation.⁷ This leads us to suggest that colonic decompression may be a more appropriate initial treatment in cases of Ogilvie syndrome secondary to stroke, followed by pharmacological intervention in refractory cases.

Conclusion

Due to the inherent autonomic dysfunction caused by stroke and leading to associated development of Ogilvie syndrome, standard pharmaceutical management does not seem to be the appropriate first-line option. Boluses of neostigmine may not be strong enough in autonomically damaged bowel walls to overcome the dysfunction causing the pseudo-obstruction. Instead, beginning with a continuous infusion of neostigmine, longer-acting acetylcholinesterase inhibitor like pyridostigmine or introduction of an additional bowel motility stimulant with an alternative mechanism of action like prucalopride may provide better relief for this subset of patients due to prolonged exposure and time for effect of the medications. We suggest that colonic decompression with subsequent decrease in tension on the bowel wall, before ischemic damage and/or perforation can occur, may be a more appropriate initial treatment, followed by pharmaceutical treatment in refractory cases of Ogilvie syndrome secondary to stroke.

Lessons Learned

Patients with Ogilvie syndrome occurring after stroke may require initial treatment differing from the current standard of care of a neostigmine bolus for cases of other etiologies. These two cases highlight the potential alternative treatments such as neostigmine continuous infusion, longer acting acetylcholinesterase inhibitors, alternative receptor agonists or colonoscopic decompression. These options may prove more beneficial as first-line therapy for Ogilvie syndrome following stroke due to the inherent autonomic dysfunction caused by stroke.

References

1. Wanklyn PD, German A. A case of refractory Ogilvie syndrome following a haemorrhagic stroke. *Clin Med.* 2013;13:623–624.
2. White L, Sandhu G. Continuous neostigmine infusion versus bolus neostigmine in refractory Ogilvie syndrome. *Am J Emerg Med.* 2011;29:76.e1–3.
3. Lee S, Na I, Choi E, et al. Occurrence of intestinal pseudo-obstruction in a brainstem hemorrhage patient. *Ann Rehabil Med* 2012;36:278–81.
4. O’Dea CJ, Brookes JH, Wattoo DA. The efficacy of treatment of patients with severe constipation or recurrent pseudo-obstruction with pyridostigmine. *Colorectal Dis* 2010;12:540–8.
5. Emmanuel AV, Kamm MA, Roy AJ, et al. Randomized clinical trial: the efficacy of prucalopride in patients with chronic intestinal pseudo-obstruction – a double-blind, placebo-controlled, cross-over, multiple $n = 1$ study. *Aliment Pharmacol Ther.* 2012;35:48–55.
6. Tsirlina VB, Zemlyak AY, Avery MJ, et al. Colonoscopy is superior to neostigmine in the treatment of Ogilvie’s syndrome. *Am J Surg.* 2012;204:849–55, discussion 855.
7. Peker KD, Cikot M, Bozkurt MA, et al. Colonic decompression should be used before neostigmine in the treatment of Ogilvie’s syndrome. *Eur J Trauma Emerg Surg.* 2017 Aug;43(4):557–566.