

# Prolonged Allograft Survival in Immunocompromised Patients

**AUTHORS:**

Kristen Hardy, BS; Cody Mullens BS;  
Ilan McCulloch BS, BA, M.Res;  
Ernest K. Manders, MD; Cristiane Ueno, MD

**CORRESPONDENCE AUTHOR:**

Kristen Hardy  
3 Shannon Place  
Charleston, WV 25314  
Email: kmhardy@mix.wvu.edu  
Phone: 304-553-2505

<b>Background</b>	Gamma-irradiated human skin allograft is an acellular, preserved cadaveric dermal skin substitute that is useful as a temporary skin substitute. <sup>1</sup> There are reported instances of long term allograft survival in patients who are immunosuppressed. <sup>2</sup> This case series demonstrates the uniquely enhanced viability of GammaGraft® for wound coverage in an immunocompromised patient being treated for acute lymphocytic leukemia.
<b>Summary</b>	We present the case of a 21-year-old male patient diagnosed with high risk T-cell acute lymphocytic leukemia (ALL) who had a large infected collection and associated necrotizing fasciitis in his left thigh; and the case of a 73-year-old female with a past medical history of metastatic breast cancer and atrial fibrillation who presented with a right knee hematoma that eventually progressed to full thickness skin necrosis. Both patients have previously been on chemotherapeutic regimes for cancer treatment. After presentation, both patients' wounds were cleared of nonviable tissue and were pulsed lavaged with sterile irrigant before being covered with GammaGraft. The patients tolerated the procedure well, and in both cases, the GammaGraft maintained adherence, vascularization, and epithelialization. Both patients' GammaGrafts have remained viable for 10 and 13 months, respectively, and have not shown signs of rejection.
<b>Conclusion</b>	Patients receiving chronic immunosuppressive therapy or patients living in a chronically immunosuppressed state are unique in that an allograft, intended for temporary wound coverage in patients who cannot immediately receive definite skin grafting, may have prolonged survival and engraftment. Our patients' ability to sustain GammaGraft for wound coverage while on chemotherapies demonstrates prolonged allograft survival in immunosuppressed patient populations and the potential use of these temporary interventions as permanent treatments.
<b>Keywords</b>	GammaGraft, wound coverage, temporary grafting, skin grafting, immunosuppression

**DISCLOSURE STATEMENT:**

This research did not receive any specific grant funding or other financial compensation in the public, commercial, or non-profit sectors. None of the authors have any conflicts of interest, financial or otherwise to disclose. However, author E.K.M. would like to disclose that they are a founder of Promethean LifeSciences, Inc., and currently serves as a Medical Director and Chief Science Officer.

**To Cite:** Hardy K, Mullens C, McCulloch I, Manders EK, Cristiane C, Mason AC. Prolonged Allograft Survival in Immunocompromised Patients. *ACS Case Reviews in Surgery*. 2020;2(5):22-27.

## Case Description

Gamma-irradiated human skin allograft is an acellular, preserved cadaveric skin graft that is useful as a temporary skin substitute.<sup>1</sup> Its utility has been buoyed by the demonstration of shorter hospital stays in patients receiving skin allografts, and the ability to create a more favorable wound bed for secondary autografting.<sup>2</sup> As with any skin replacement, gamma-irradiated grafts decrease the loss of water, electrolytes, and heat from wound beds. Further, it serves as a mechanical barrier to prevent unwanted microbial invasion<sup>3</sup> and to reduce catabolic losses which allows patients to metabolically recover.

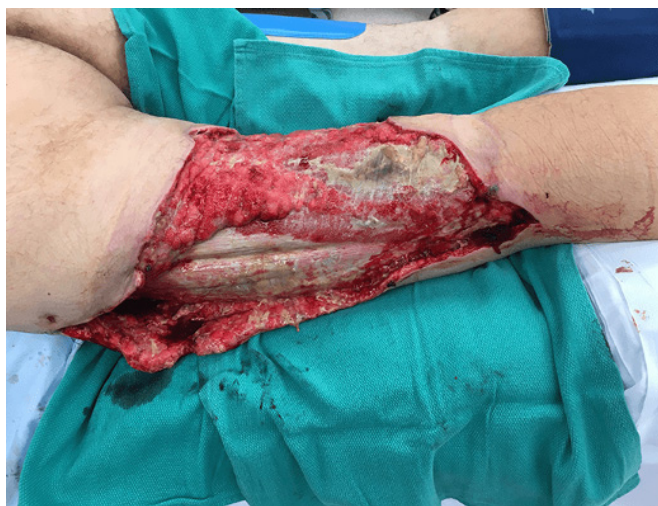The gamma irradiation process sterilizes allografts by exposing the tissues to high-energy photons (gamma rays). This sterilization largely eliminates the possibility of disease transmission from the cadaveric donor to the recipient. Early non-gamma-irradiated allografts were not as easily used as current commercially available products. Newer processing for products such as GammaGraft permits storage at room temperature for up to six years.

This has increased the usage of gamma-irradiated allografts among reconstructive surgeons for temporary wound closure.<sup>7</sup>

In the following two cases, GammaGraft was intended for temporary wound coverage of large lower-extremity wounds but resulted in longer term engraftment likely due to the immunocompromised state of the patients. Although GammaGraft is often used for temporary wound coverage, there are a few reported instances of long-term survival of GammaGraft in patients who are immunosuppressed.<sup>9</sup> The majority of reports involve patients post-solid organ transplantation. In the cases described here, immunosuppression is due to chemotherapeutic regimes in the treatment of acute lymphocytic leukemia and metastatic breast cancer. Their respective therapies included antifolate therapy (Methotrexate) and capecitabine (Xeloda), which delay the ability of the immune response to allografts. Thus, this case series demonstrates the increased viability of GammaGraft used for wound coverage in two immunocompromised patients.

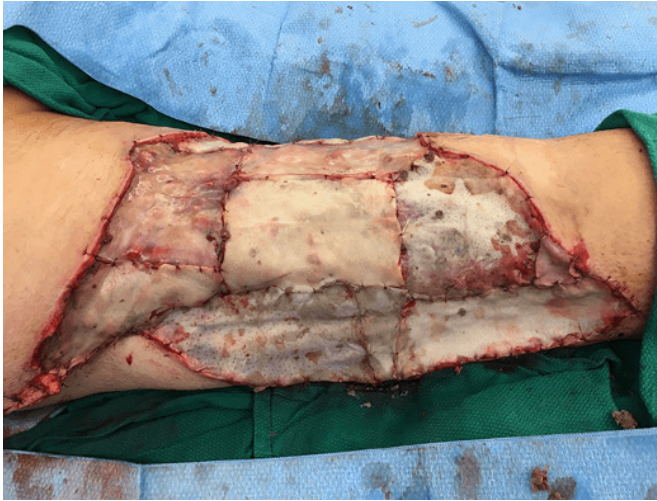## Case 1

Patient 1 is a 21-year-old male with a history of high-risk T-cell acute lymphocytic leukemia (ALL). He was receiving induction chemotherapies when he presented with a large infected collection and associated necrotizing fasciitis in his left thigh (Figure 1). His chemotherapeutic regimen included cytarabine, methotrexate, and cyclophosphamide. After resuscitation and stabilization, surgical drainage of the collection and debridement of all nonviable skin and soft tissue was performed resulting in a large wound around the upper left leg. The final defect measured 31x41 centimeters (cm) in size. Wound cultures revealed *Pseudomonas aeruginosa* and he was treated with cefepime and doxycycline. Due to his acute and immunocompromised status definitive skin grafting was deferred. However, coverage of the wound was elected using a cadaveric allograft, GammaGraft. The wound was debrided of all nonviable tissue and pulse-lavaged with sterile irrigant. GammaGraft was applied over the lateral, medial, and posterior aspects of the left upper leg and secured using interrupted 4-0 chromic sutures (Figure 2). The graft was placed with the dermal side down as the dermal structure creates an environment that allows rapid migration and proliferation of fibroblasts and revascularization of the wound site.<sup>8</sup> Xeroform gauze covered the area and the extremity was wrapped with elastic compression bandages. He tolerated the procedure well and recovered from his systemic inflammatory response. At 8 months post placement, the GammaGraft remains adherent, vascularized, and epithelialized (Figure 3). He has continued his chemotherapy treatment for ALL uninterrupted and is currently in remission by last bone marrow aspirate.

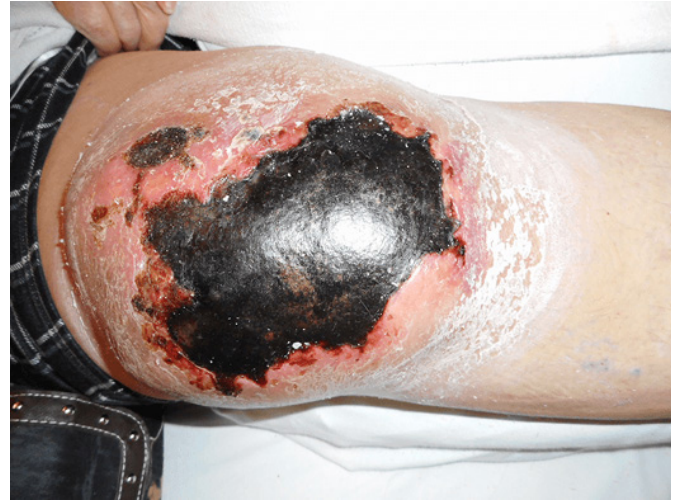

**Figure 1.** Pre-operative leg wound prior to debridement

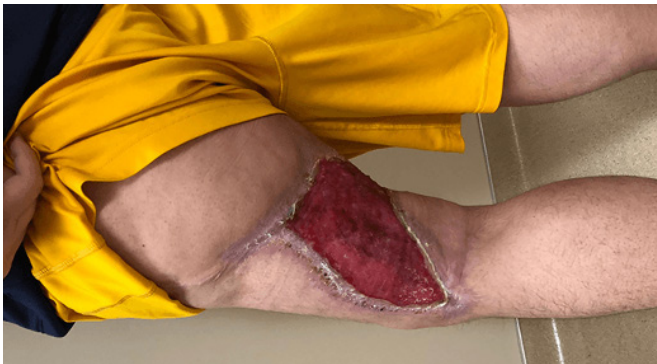



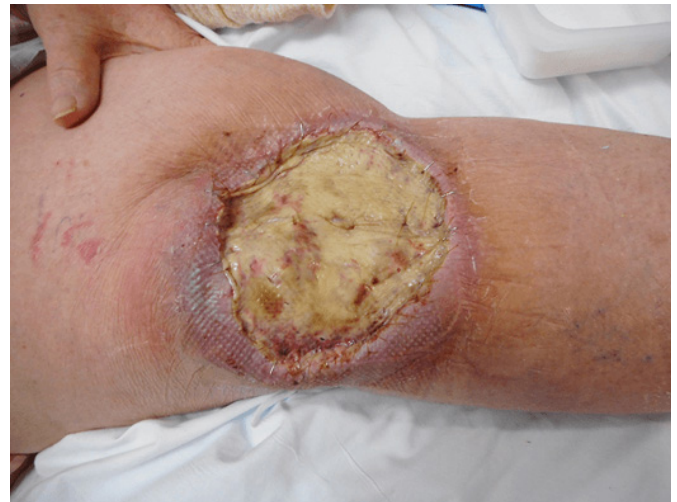**Figure 2.** Post-operative leg wound following debridement and coverage with GammaGraft



**Figure 4.** Right knee hematoma at presentation



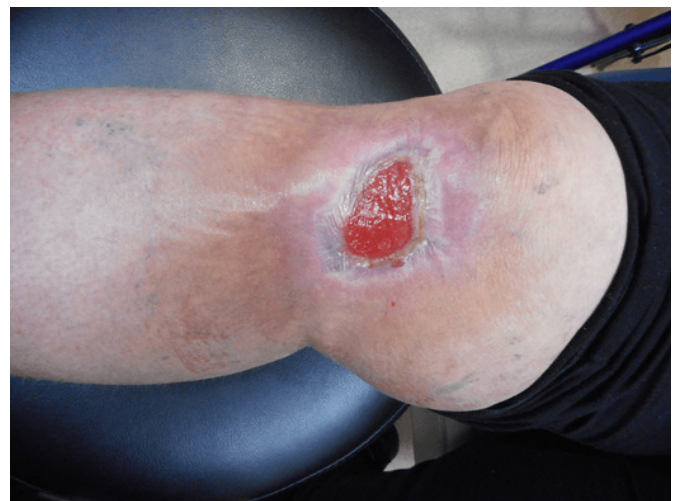
**Figure 3.** Leg wound at 8-months post-operation



**Figure 5.** GammaGraft coverage of knee wound

## Case 2

Patient 2 is a 73-year-old female with a past medical history of metastatic breast cancer and atrial fibrillation on chronic warfarin who presented with a right knee hematoma (Figure 4), which progressed to full thickness skin necrosis. Her metastatic breast cancer was being treated with capecitabine (Xeloda). She later fell upon her right knee, which resulted in a large hematoma and pressure related skin necrosis. She underwent evacuation of the hematoma and debridement of all nonviable tissue resulting in a 12x12 cm wound. Deep wound cultures collected intraoperatively grew *Escherichia coli* and *Finogoldia magna* that were treated with trimethoprim/sulfasulfamethoxazole according to sensitivities. The defect was covered with GammaGraft (Figure 5) and secured with interrupted 4-0 chromic sutures. She tolerated the procedure well and continues to recover. At four months follow up the graft shows good adherence, neovascularization, and epithelialization (Figure 6), and patient remains on her chemotherapy treatment uninterrupted.



**Figure 6.** Wound at 4-months post-operation

## Discussion

Allografts are temporary, biologic dressings that minimize fluid and protein loss, their high antigenicity prevents permanent engraftment in most settings.<sup>14</sup> The mechanism of allograft rejection is attributed to T-cell infiltration and cytotoxic differentiation of intra-graft CD8+ T-cells.<sup>15</sup> Irradiated allografts do not exhibit vascular in-growth and T-cell invasion like non-irradiated allografts. In these irradiated allografts, primary phase rejection at four weeks is not seen and in an immunocompetent patient GammaGraft will routinely adhere for 6 to 8 weeks. In the immunosuppressed patient, however, this rejection mechanism is further slowed. This enables the allograft to serve as long term coverage, often for multiple weeks and even months.<sup>14</sup> In some cases, immunosuppression facilitates allograft survival for as long as the patient remains in an immunocompromised state.<sup>14,16</sup>

The role of immunosuppression in promoting allograft engraftment has been studied in a variety of animal studies (Table 1).<sup>15,17-20</sup>

Most of these studies emphasize that compromised T-cell and antigen-presenting cell function leads to improved survival and engraftment of the allograft. Qing Ding et al. demonstrated a link between the expression of IFN- $\gamma$ , an inflammatory mediator regulated by B cells in the immune response, and accelerated islet allograft rejection in rats. This study demonstrated that pharmacological interventions that decrease the expression of IFN- $\gamma$  can promote allograft tolerance.<sup>18</sup> In a group of mice receiving fully mismatched skin allografts, the use of FTY720—an immunosuppressive agent that works by reducing the amount of circulating T-cells<sup>15</sup>—and, in a subsequent study, the addition of cyclosporine prolonged the allograft survival for the 21 days that these drugs were administered.<sup>19</sup> This study did not mention the outcome of the allograft after the immunosuppressive therapy was discontinued. Another group showed that inhibiting lymphatic drainage from skin allografts in rats promoted the survival of allografts and suppressed the immunological events that occur after transplantation that normally lead to rejection.<sup>20</sup>

References	Immunosuppression	Species	N	Mean Allograft Survival
<b>Lima et al.</b>	FTY720	Mouse	3 per group	16.6 $\pm$ 4.2 days
<b>Silva et al.</b>	FTY720 + Cyclosporine	Mouse	5	Each of the groups receiving only one agent alone showed average survival of 11.9 $\pm$ 0.8 day. The combination group did not show rejection until day 21.
<b>Pei et al</b>	Allograft lymphatic drainage inhibition	Mouse	15	15 days
<b>Olariu et al</b>	Tacrolimus	Rat	8	200 days
<b>Delikonstantinou et al</b>	Azathioprine + Prednisolone	Human	1	3 weeks, but a variable degree of vascularized allo-dermis was present despite rejection.
<b>Mindikoglu &amp; Ctinkale</b>	Cyclosporine	Human	1	survived during the 3 months of immunosuppressive therapy, but rejection occurred 12 days after discontinuation of cyclosporine.
<b>Vyas et al</b>	CML, Tacrolimus, Prednsione, Mycophenolate mofetil	Human	1	At 5 months post grafting, the patient had fully vascularized intact skin.

**Table 1.** Summary of literature describing increased survival in allografts in immunosuppressed recipients

In humans, some case studies have shown that immunosuppressive therapy can extend allograft survival. In a case report by Delikonstantinou, a woman undergoing an immunosuppressive regimen consisting of Azathioprine and Prednisolone following a liver transplant received a human skin allograft for coverage of a burn wound.<sup>16</sup> Though there was no prolonged survival of the allo-epidermis in this case, the immunosuppression allowed the allo-dermis to achieve a variable degree of vascularization and serve as a scaffold for the subsequent skin autografting.<sup>16</sup> In a separate case, a woman with extensive burns was administered cyclosporine to extend the survival of her skin allografts obtained from several unmatched donors. During the cyclosporine treatment regimen, there was no evidence of graft rejection, but twelve days after discontinuing the drug, allograft rejection became apparent.<sup>14</sup> Similar to our two patients, a recent case report described a man receiving chronic immunosuppression post hepato-renal transplantation who demonstrated prolonged survival of his skin allograft following necrotizing fasciitis.<sup>9</sup>

Though the use of systemic immunosuppression has been shown to improve allograft survival, non-systemic methods are being explored to avoid increasing infectious risks. One proposed method is local immunosuppression at the site of the graft. Olariu et al. demonstrated the efficacy of this technique in rat hind-limb transplantation.<sup>17</sup> The animals receiving an intra-graft high-dose injection of tacrolimus 1-day post-operation showed an increase of graft survival without inducing liver or kidney toxicity that can occur with chronic immunosuppression.<sup>17</sup>

From these reports, it appears that patients receiving immunosuppressive therapy are unique in that an allograft may demonstrate prolonged survival and they may benefit from more sustained wound coverage. Our two patients' ability to sustain GammaGraft as long-term wound coverage while on chemotherapies further demonstrates the potential for temporary allografts to serve as long-term wound coverage in this specific patient population.

## Conclusion

This case series demonstrates instances of long-term GammaGraft survival in two chronically immunosuppressed patient well beyond its usual viability of 8 weeks, and in both cases GammaGraft served as a form of permanent wound coverage. Although GammaGraft has been considered a temporary intervention in the past, these cases

demonstrate the utility of GammaGraft as a viable option for long-term and perhaps even permanent means of wound coverage in immunosuppressed patient populations.

## Lessons Learned

This series introduces the extended utility of the temporary skin substitute GammaGraft as a more long-term option for wound coverage in certain patient populations. As demonstrated by the cases presented, patients receiving immunosuppressive therapies may show epithelization and vascularization of these grafts, removing the need for replacement with a permanent means of wound coverage.

## References

1. Rosales MA, Bruntz M, Armstrong DG. Gamma-irradiated human skin allograft: a potential treatment modality for lower extremity ulcers. *Intl Wound J.* 2004;1(3):201-206.
2. Pruitt BA, Levine NS. Characteristics and uses of biologic dressings and skin substitutes. *Arch Surg.* 1984;119(3):312-322.
3. Rooney P, Eagle M, Hogg P, Lomas R, Kearney J. Sterilisation of skin allograft with gamma irradiation. *Burns.* 2008;34(5):664-673.
4. Eagle M, Rooney P, Lomas R, Kearney J. Validation of radiation dose received by frozen unprocessed and processed bone during terminal sterilisation. *Cell Tissue Bank.* 2005;6(3):221-230.
5. Kreis R, Vloemans A, Hoekstra M, Mackie D, Hermans R. The use of non-viable glycerol-preserved cadaver skin combined with widely expanded autografts in the treatment of extensive third-degree burns. *J Trauma Acute Care.* 1989;29(1):51-54.
6. Bourroul SC, Herson MR, Pino E, Mathor MB. Sterilization of skin allografts by ionizing radiation. *Cell Mol Biol.* 2002;48(7):803-808.
7. Singh R, Singh D, Singh A. Radiation sterilization of tissue allografts: A review. *World J Radiol.* 2016;8(4):355.
8. Nathoo R, Howe N, Cohen G. Skin substitutes: an overview of the key players in wound management. *J Clin Aesthet Dermatol.* 2014;7(10):44.
9. Vyas KS, Burns C, Ryan DT, Wong L. Prolonged Allograft Survival in a Patient With Chronic Immunosuppression: A Case Report and Systematic Review. *Wounds.* 2017;29(6):159.
10. Boer JM, den Boer ML. BCR-ABL1-like acute lymphoblastic leukaemia: From bench to bedside. *Eur J Cancer.* 2017;82:203-218.
11. Hasham S, Matteucci P, Stanley PR, Hart NB. Necrotising fasciitis. *BMJ.* 2005;330(7495):830.



12. Jaing T-H, Huang C-S, Chiu C-H, Huang Y-C, Kong M-S, Liu W-M. Surgical implications of *Pseudomonas aeruginosa* necrotizing fasciitis in a child with acute lymphoblastic leukemia. *J Pediatr Surg*. 2001;36(6):948-950.
13. Emmett C, Kane G. Necrotising fasciitis caused by *P aeruginosa* in a male patient with chronic lymphocytic leukaemia. *BMJ Case Rep*. 2013;2013:bcr2012008133.
14. Mindikoğlu A, Cetinkale O. Prolonged allograft survival in a patient with extensive burns using cyclosporin. *Burns*. 1993;19(1):70-72.
15. Lima R, Nogueira-Martins M, Silva H, Pestana J, Bueno V. FTY720 treatment prolongs skin graft survival in a completely incompatible strain combination. Paper presented at: Transplantation proceedings 2004.
16. Delikonstantinou I, Philp B, Kamel D, Barnes D, Dziewulski P. A major burn injury in a liver transplant patient. *Ann Burns Fire Disasters*. 2016;29(3):206.
17. Olariu R, Denoyelle J, Leclère FM, et al. Intra-graft injection of tacrolimus promotes survival of vascularized composite allotransplantation. *J Surg Res*. 2017;218:49-57.
18. Ding Q, Mohib K, Kuchroo VK, Rothstein DM. TIM-4 Identifies IFN- $\gamma$ -Expressing Proinflammatory B Effector 1 Cells That Promote Tumor and Allograft Rejection. *J Immunol*. 2017;199(7):2585-2595.
19. Silva, Francieli Ruiz, et al. "FTY720 In Combination with Cyclosporine: an Analysis of Skin Allograft Survival and Renal Function." *Int Immunopharmacol*. Vol. 6, no. 13-14, 2006, pp. 1911-1918.
20. Pei J, Li Y, Chen C, et al. Inhibition of Lymphatic Drainage With a Self-Designed Surgical Approach Prolongs the Vascularized Skin Allograft Survival in Rats. *Ann Plas Surg*. 2018; 80(1): 76-82.