

# Recurrence of Stage IV Melanoma to the Spleen with Splenomegaly Treated with Laparoscopic Splenectomy

**AUTHORS:**

Khrucharoen U<sup>a,b</sup>; Joo Y-Y<sup>a,b</sup>; Wongpongsalee T<sup>a,b,c</sup>;  
Dutson EP<sup>a,b</sup>

**CORRESPONDING AUTHOR:**

Erik P. Dutson, MD, FACS  
Section of Minimally Invasive and Bariatric  
Surgery, David Geffen School of Medicine at  
University of California  
UCLA Center for Advanced Surgical &  
Interventional Technology (CASIT)  
BOX 956904, 72-239 CHS  
Los Angeles, CA 90095  
Phone: (310) 206-7235  
Email: edutson@mednet.ucla.edu

**AUTHOR AFFILIATIONS:**

a. Section of Minimally Invasive and Bariatric  
Surgery  
Department of Surgery  
David Geffen School of Medicine at University of  
California  
Los Angeles, CA 90095

b. UCLA Center for Advanced Surgical &  
Interventional Technology (CASIT)  
Los Angeles, CA 90095

c. Division of Trauma Surgery  
Department of Surgery  
Faculty of Medicine Siriraj Hospital, Mahidol  
University  
Bangkok 10700, Thailand

<b>Background</b>	A male patient diagnosed with cutaneous malignant melanoma presented with oligometastasis to the spleen.
<b>Summary</b>	The patient is a 70-year-old male who presented with recurrent metastatic melanoma to the spleen. He was initially diagnosed with cutaneous malignant melanoma stage cT3aN0M0 on the right ear lobe. A year prior to presentation, he developed a recurrence at the primary site, and subsequently went on to develop metastatic disease to the right upper arm, anterior and middle mediastinum, liver, spleen, and retroperitoneum. The patient was treated with nivolumab and appeared to have an excellent response with complete resolution of metastatic disease, confirmed by whole-body PET/CT scan. The patient had a 12-month disease-free interval. The following year, his PET/CT scan showed an isolated splenic mass with increasing size and metabolic activity and associated splenomegaly. Following a multidisciplinary tumor board discussion, the consensus was to perform metastasectomy, and the patient subsequently underwent laparoscopic splenectomy followed by adjuvant systemic therapy. Final pathology showed metastatic melanoma with treatment effect with negative lymph nodes (0/7). A combination of metastasectomy and systemic therapy has been shown to improve overall survival in selected patients dramatically.
<b>Conclusion</b>	We present a rare case of recurrent isolated metastatic melanoma to the spleen treated with laparoscopic splenectomy. Metastasectomy in resectable disease can improve overall survival. Adjuvant systemic therapy is recommended following surgical resection.
<b>Key Words</b>	recurrent metastatic melanoma; metastasectomy; laparoscopic splenectomy

**DISCLOSURE STATEMENT:**

The authors have no relevant financial relationships to disclose.

**FUNDING/SUPPORT:**

The authors have no relevant financial relationships or in-kind support to disclose.

**MEETING PRESENTATION:**

ACS Clinical Congress 2019, San Francisco, CA, October 2019

**RECEIVED:** July 14, 2020

**REVISION RECEIVED:** November 9, 2020

**ACCEPTED FOR PUBLICATION:** December 7, 2020

**To Cite:** Khrucharoen U, Joo Y-Y, Wongpongsalee T, Dutson EP. Recurrence of Stage IV Melanoma to the Spleen with Splenomegaly Treated with Laparoscopic Splenectomy. *ACS Case Reviews in Surgery*. 2022;3(8):12-16.

## Case Description

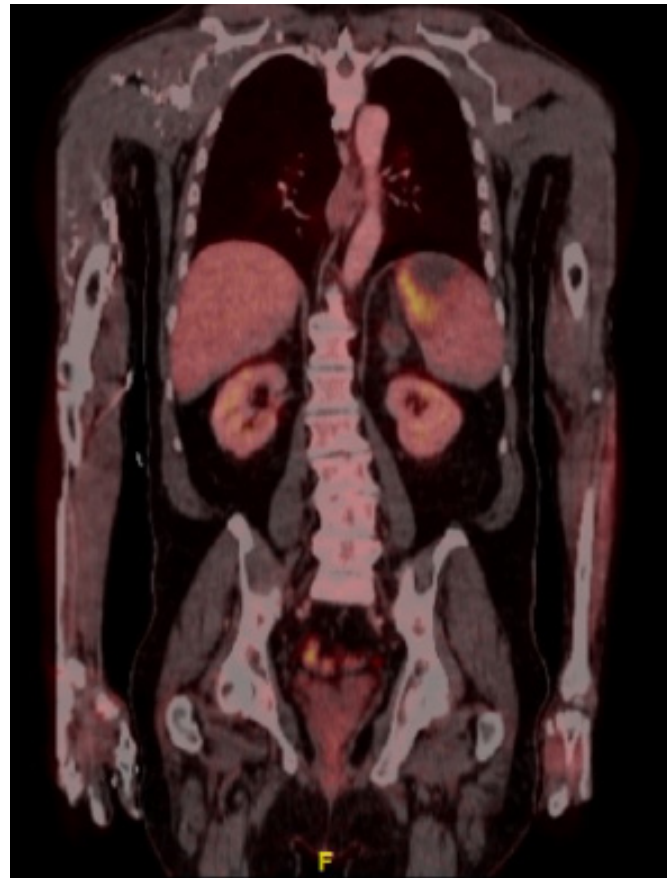
The spleen is usually an uncommon site of metastatic disease.<sup>1</sup> The most common metastatic sites of malignant melanoma include the skin and lung, followed by lymph nodes, brain, liver, and gastrointestinal (GI) tract, respectively.<sup>2</sup> We reported a rare presentation of a recurrence of BRAF V600K mutated metastatic melanoma to the spleen.

The patient is a 70-year-old male referred for increasing metastatic melanoma to the spleen. He was diagnosed with cutaneous malignant melanoma stage T3a on the right ear lobe 15 years prior to presentation. Four years before presentation, the patient developed a recurrence and underwent excision and radiation. He subsequently developed metastatic disease to the right upper arm, anterior and middle mediastinum, liver, spleen, and retroperitoneum. The BRAF V600K mutation was detected, and the patient was initially treated with a combination of BRAF inhibitor (dabrafenib) and MEK inhibitor (trametinib). However, he did not tolerate the combination therapy. The tumor cells were found to have 10% expression of the programmed death-ligand 1 (PD-L1). The patient was subsequently started on a programmed death-1 (PD-1) blocker (nivolumab). He appeared to have an excellent response to nivolumab with complete resolution of metastatic disease for 12 months. However, two years later, his positron emission tomography-computed tomography (PET/CT) scan showed splenomegaly with a splenic mass consistent with likely metastatic disease. No biopsy was performed. Figure 1 shows a PET/CT scan taken a year following the discovery. Lactate dehydrogenase (LDH) was found to be slightly increased (268 U/L).

In this case, the patient had no evidence of metastatic melanoma elsewhere except for the spleen. The patient was offered surgical resection of this isolated metastasis via total splenectomy with adjuvant systemic therapy.

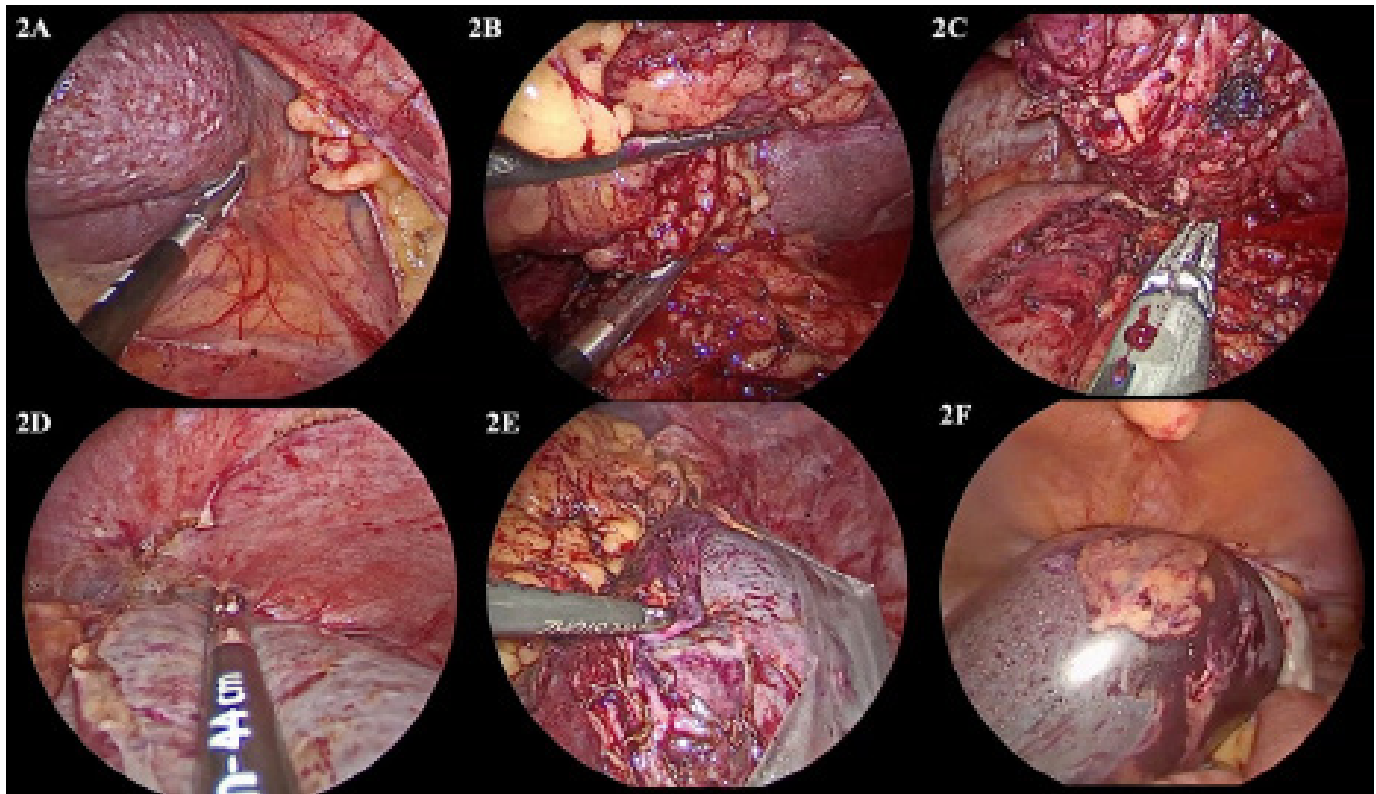
The patient successfully underwent laparoscopic splenectomy with an uneventful postoperative course. The intraoperative findings were demonstrated in Figures 2A to 2F. The specimen was removed with an Endo Catch™ bag through a mini-Pfannenstiel incision without morcellation. Final pathology showed a 734-gram, 18.9 × 13.0 × 8.4 cm spleen with necrotic-appearing 12.2 × 5.5 cm and 0.5 × 0.5 cm nodules. Immunohistochemistry was posi-

Figure 1. PET/CT Scan. Published with Permission



Scan shows hypoenhancing bilobed splenic lesion with rim of intense hypermetabolism in its medial aspect consistent with metabolically active tumor.

tive for S100, MART1, HMB45, and SOX10, suggesting metastatic melanoma with treatment effect, ypT0N0M1. All seven harvested lymph nodes found in the surrounding tissues and ligaments were negative for malignancy. The patient was discharged on postoperative day 3 with oral pain medication and continuing monthly Nivolumab following complete resection. The patient completed a one-year course of Nivolumab without recurrence.

**Figure 2.** Intraoperative Techniques and Findings. Published with Permission

A) Dissection was carried out along splenicocolic and splenorenal ligaments using Ligasure following complete dissection of gastrosplenic ligament. B & C) The spleen was retracted superiorly, and dissection was carried out around splenic hilum; Endo GIA 60-mm articulating stapler was used to divide the hilum completely. D) Spleen was dissected from diaphragm; and E & F) specimen was retrieved with Endo Catch™ bag and removed intact through mini-Pfannenstiel incision.

## Discussion

The incidence of cutaneous malignant melanoma varies across countries, with 287,723 cases of newly diagnosed and 60,712 deaths reported worldwide in 2018.<sup>3</sup> Malignant melanoma is one of the most common skin cancers in the United States, with an increasing incidence over the past decade.<sup>4</sup> The five-year overall survival reported was 95 to 100% in stage I, 65 to 92% in stage II, 41 to 74% in stage III, and 9 to 28% in stage IV.<sup>5</sup>

Patterns of metastasis in advanced melanoma are unpredictable. The majority of patients (71 to 86%) were found to have one metastatic site, with the skin, lung, lymph node, liver, and small bowel being the most common sites of metastasis, respectively.<sup>2,6</sup> Distant metastatic melanoma to other visceral organs is rare, especially in the spleen. However, it has been reported in case reports and case series.<sup>7-11</sup> In our case, the patient developed a recurrence of metastatic melanoma to the spleen following complete resolution of metastatic disease with excellent response to the immune checkpoint inhibitor therapies. Following

a multidisciplinary tumor board discussion, a consensus was to resect this oligometastatic lesion given the patient's excellent response to anti-PD1 therapy, 12-month disease-free interval, and good performance status. Because the patient had an excellent response to nivolumab and did not tolerate a combination of BRAF inhibitor and MEK inhibitor in the past, the patient was recommended to continue nivolumab for one year following splenectomy as per NCCN guidelines 2019.<sup>12</sup>

In this case, due to concerns for recurrence and increased risk of intraabdominal dissemination and potential port site implantation,<sup>13-15</sup> the specimen was retrieved with an impermeable bag without mechanical morcellation and removed through a mini-Pfannenstiel incision. In patients with metastatic melanoma to abdominal solid organs, minimizing tumor spread at any level must be considered during performing resection, such as minimizing tumor manipulation, avoiding tumor mass or solid organ capsule violation, avoiding morcellation, and utilizing an impermeable bag to retrieve the specimen.<sup>16,17</sup>

Management of malignant melanoma has evolved tremendously since the introduction of the immune checkpoint inhibitor therapies and BRAF-targeted therapy. Surgical resection of the primary lesion is still the main treatment for stage I-III melanoma.<sup>12</sup> In the past, treatment of distant metastasis was such that resection was not indicated, except for palliation. However, with the emergence of effective systemic therapies, the combination of metastasectomy and systemic therapy has been shown to dramatically improve overall survival in selected patients.<sup>6,18-20</sup> Surgical resection has been shown to be superior over medical treatment alone in terms of median survival in these patients.<sup>19</sup> A favorable outcome was found with metastasectomy, especially in those with gastrointestinal tract metastasis, with more than 50% survival in the first year and 33% at five years. Those with liver, spleen, and pancreas metastases also experienced a significant benefit compared to those treated non-surgically.<sup>19</sup> In the modern era of effective systemic therapy along with metastasectomy in patients with stage IV melanoma, median overall survival has improved from 27 months to 64 months; additionally, five-year melanoma-specific survival rate increased from 24% to 46%.<sup>6,19</sup> Metastasectomy is considered an excellent option in patients with low-volume and isolated metastatic disease as well as in those with resectable residual disease following targeted and immune therapies.<sup>21</sup> Surgical resection can remove tumor burden disease in a shorter treatment interval than systemic therapy alone; it was found to have better tolerance than systemic therapies.<sup>22</sup> Removal of tumor burden can potentially reduce melanoma-induced immunosuppression, thus enhancing the efficacy of systemic immunotherapies.<sup>23,24</sup> However, not all stage IV melanoma patients are eligible for metastasectomy. Patient selection remains a crucial process in successful management.

With the improvement of surgical techniques, laparoscopic splenectomy has been shown to have reduced morbidity compared to the standard open approach.<sup>25,26</sup> Although no prospective studies comparing open and laparoscopic techniques in this particular population have been conducted, laparoscopic splenectomy in isolated metastatic disease is feasible in selected patients.<sup>27</sup> Additionally, retrospective studies have shown patients undergoing laparoscopic splenectomy were found to have a shorter length of hospital stay and recovery time compared to patients undergoing open splenectomy.<sup>9,26</sup>

## Conclusion

We present a rare case of recurrent isolated metastatic melanoma to the spleen treated with laparoscopic splenectomy. Metastasectomy in resectable disease can improve overall survival. Adjuvant systemic therapy is recommended following surgical resection.

## Lessons Learned

A combination of metastasectomy and systemic therapy may improve overall survival for patients with resectable and low-volume metastatic disease. Laparoscopic splenectomy in isolated metastatic disease is feasible in selected patients.

## References

1. Pugalenti A, Bradley C, Gonen M, et al. Splenectomy to treat splenic lesions: an analysis of 148 cases at a cancer center. *J Surg Oncol*. 2013;108(8):521-525. doi:10.1002/jso.23433
2. Barth RJ Jr, Venzon DJ, Baker AR. The prognosis of melanoma patients with metastases to two or more lymph node areas. *Ann Surg*. 1991;214(2):125-130. doi:10.1097/00000658-199108000-00006
3. Bray F, Ferlay J, Soerjomataram I, Siegel RL, Torre LA, Jemal A. Global cancer statistics 2018: GLOBOCAN estimates of incidence and mortality worldwide for 36 cancers in 185 countries [published correction appears in *CA Cancer J Clin*. 2020 Jul;70(4):313]. *CA Cancer J Clin*. 2018;68(6):394-424. doi:10.3322/caac.21492
4. Peterson M, Albertini MR, Remington P. Incidence, Survival, and Mortality of Malignant Cutaneous Melanoma in Wisconsin, 1995-2011. *WMJ*. 2015;114(5):196-201.
5. Svedman FC, Pillas D, Taylor A, Kaur M, Linder R, Hansson J. Stage-specific survival and recurrence in patients with cutaneous malignant melanoma in Europe - a systematic review of the literature. *Clin Epidemiol*. 2016;8:109-122. Published 2016 May 26. doi:10.2147/CLEP.S99021
6. Nelson DW, Fischer TD, Graff-Baker AN, et al. Impact of Effective Systemic Therapy on Metastasectomy in Stage IV Melanoma: A Matched-Pair Analysis. *Ann Surg Oncol*. 2019;26(13):4610-4618. doi:10.1245/s10434-019-07487-5
7. Mudan S, Kumar J, Mafalda NC, et al. Case report on the role of radiofrequency-assisted spleen-preserving surgery for splenic metastasis in the era of checkpoint inhibitors [published correction appears in *Medicine (Baltimore)*. 2017 Dec;96(52):e9529]. *Medicine (Baltimore)*. 2017;96(49):e9106. doi:10.1097/MD.00000000000009106

8. Reccia I, Pisanu A, Podda M, Uccheddu A. An uncommon presentation of metastatic melanoma: a case report. *Medicine (Baltimore)*. 2015;94(7):e319. doi:10.1097/MD.0000000000000319
9. De Roeck L, Wuyts L, Peters B, Ruppert M. 5-Year survival after splenectomy in a patient with recurrent cutaneous melanoma: a case report. *Acta Chir Belg*. 2018;118(6):384-387. doi:10.1080/00015458.2017.1399661
10. de Wilt JH, McCarthy WH, Thompson JF. Surgical treatment of splenic metastases in patients with melanoma. *J Am Coll Surg*. 2003;197(1):38-43. doi:10.1016/S1072-7515(03)00381-8
11. Ornellas LC, Lanzoni VP, Toledo CF. Malignant melanoma with liver and spleen metastases: case report. *Sao Paulo Med J*. 2000;118(2):53-56. doi:10.1590/s1516-3180200000200006
12. Coit DG, Thompson JA, Albertini MR, et al. Cutaneous Melanoma, Version 2.2019, NCCN Clinical Practice Guidelines in Oncology. *J Natl Compr Canc Netw*. 2019;17(4):367-402. doi:10.6004/jnccn.2019.0018
13. Howard JH, Thompson JF, Mozzillo N, et al. Metastasectomy for distant metastatic melanoma: analysis of data from the first Multicenter Selective Lymphadenectomy Trial (MSLT-I). *Ann Surg Oncol*. 2012;19(8):2547-2555. doi:10.1245/s10434-012-2398-z
14. Saraiva P, Rodrigues H, Rodrigues P. Port site recurrence after laparoscopic adrenalectomy for metastatic melanoma. *Int Braz J Urol*. 2003;29(6):520-521. doi:10.1590/s1677-55382003000600007
15. Lee EY, Heiken JP, Huettner PC. Late recurrence of malignant melanoma presenting as peritoneal "carcinomatosis". *Abdom Imaging*. 2003;28(2):284-286. doi:10.1007/s00261-002-0039-x
16. Mutter D, Hajri A, Tassetti V, Solis-Caxaj C, Aprahamian M, Marescaux J. Increased tumor growth and spread after laparoscopy vs laparotomy: influence of tumor manipulation in a rat model. *Surg Endosc*. 1999;13(4):365-370. doi:10.1007/s004649900991
17. Alieva M, van Rheeën J, Broekman MLD. Potential impact of invasive surgical procedures on primary tumor growth and metastasis. *Clin Exp Metastasis*. 2018;35(4):319-331. doi:10.1007/s10585-018-9896-8
18. Wood TE, DiFronzo LA, Rose DM, et al. Does complete resection of melanoma metastatic to solid intra-abdominal organs improve survival?. *Ann Surg Oncol*. 2001;8(8):658-662. doi:10.1007/s10434-001-0658-4
19. Deutsch GB, Flaherty DC, Kirchoff DD, et al. Association of Surgical Treatment, Systemic Therapy, and Survival in Patients With Abdominal Visceral Melanoma Metastases, 1965-2014: Relevance of Surgical Cure in the Era of Modern Systemic Therapy [published correction appears in *JAMA Surg*. 2018 Nov 1;153(11):1064]. *JAMA Surg*. 2017;152(7):672-678. doi:10.1001/jamasurg.2017.0459
20. Faries MB, Mozzillo N, Kashani-Sabet M, et al. Long-Term Survival after Complete Surgical Resection and Adjuvant Immunotherapy for Distant Melanoma Metastases. *Ann Surg Oncol*. 2017;24(13):3991-4000. doi:10.1245/s10434-017-6072-3
21. Ollila DW, Lopez NE, Hsueh EC. Metastasectomy for Stage IV Melanoma in the Era of Effective Systemic Agents. *Crit Rev Oncog*. 2016;21(1-2):37-55. doi:10.1615/CritRevOncog.2016014729
22. Leung AM, Hari DM, Morton DL. Surgery for distant melanoma metastasis. *Cancer J*. 2012;18(2):176-184. doi:10.1097/PPO.0b013e31824bc981
23. Liu J, Blake SJ, Yong MC, et al. Improved Efficacy of Neoadjuvant Compared to Adjuvant Immunotherapy to Eradicate Metastatic Disease. *Cancer Discov*. 2016;6(12):1382-1399. doi:10.1158/2159-8290.CD-16-0577
24. Huang AC, Postow MA, Orlowski RJ, et al. T-cell invigoration to tumour burden ratio associated with anti-PD-1 response. *Nature*. 2017;545(7652):60-65. doi:10.1038/nature22079
25. Musallam KM, Khalife M, Sfeir PM, et al. Postoperative outcomes after laparoscopic splenectomy compared with open splenectomy. *Ann Surg*. 2013;257(6):1116-1123. doi:10.1097/SLA.0b013e318275496a
26. Winslow ER, Brunt LM. Perioperative outcomes of laparoscopic versus open splenectomy: a meta-analysis with an emphasis on complications. *Surgery*. 2003;134(4):647-655. doi:10.1016/s0039-6060(03)00312-x
27. Lopez Monclova J, Targarona Soler E, Peraza Solis Y, et al. Laparoscopic approach for isolated splenic metastasis: comprehensive literature review and report of 6 cases. *Surg Laparosc Endosc Percutan Tech*. 2013;23(1):21-24. doi:10.1097/SLE.0b013e318277b009