

# Intraperitoneal Bladder Rupture in the Postrenal Transplant Period

**AUTHORS:**

Brooks AL<sup>a,b</sup>; Jureller M<sup>a</sup>; Muhdi NA<sup>a</sup>; Yaffe H<sup>a,b</sup>;  
Le ME<sup>a,b</sup>; Graham JA<sup>a,b</sup>; Greenstein S<sup>a,b</sup>; Rocca JP<sup>a,b</sup>

**CORRESPONDING AUTHOR:**

Abigail L. Brooks, MD  
111 E. 210 Street  
Rosenthal Building, Floor 2  
Bronx, NY 10461  
Email: abbrooks@montefiore.org

**AUTHOR AFFILIATIONS:**

a. Division of Hepatobiliary Surgery and  
Abdominal Organ Transplantation  
Montefiore Medical Center  
Bronx, NY 10467

b. Albert Einstein College of Medicine  
Bronx, NY 10461

|                      |  |
|----------------------|--|
| <b>Background</b>    | A male patient presented 16 days following deceased-donor renal transplant with a spontaneous intraperitoneal bladder rupture unrelated to the uretero-neocystostomy anastomosis.  |
| <b>Summary</b>       | We present a case of postrenal transplant spontaneous bladder rupture due to increased urinary output, successfully managed with laparoscopic repair. Our patient, who had undergone deceased-donor renal transplant for end-stage renal disease secondary to hypertension after six years of anuria, presented to the emergency department with abdominal pain and difficult urination shortly after discharge. Examination revealed peritoneal signs, and imaging confirmed urine peritonitis from a urinary leak. Surgical exploration revealed an intact extraperitoneal anastomosis and intraperitoneal bladder rupture, likely due to bladder outlet obstruction post-transplant. This case highlights the occurrence of spontaneous bladder rupture after renal transplant and the laparoscopic approach to diagnosis and repair. |
| <b>Conclusion</b>    | Intraperitoneal bladder rupture distinct from the original ureteroneocystostomy may be seen in patients at risk for bladder outlet obstruction, such as older males with benign prostatic hyperplasia. This case highlights the use of laparoscopic repair of spontaneous bladder rupture as a successful, minimally invasive management.  |
| <b>Key Words</b>     | spontaneous bladder rupture; bladder outlet obstruction; laparoscopic repair of bladder rupture; intraperitoneal bladder rupture   |
| <b>Abbreviations</b> | COVID-19: coronavirus disease 2019, PSA: prostate-specific antigen, KDPI: kidney donor profile index, BMI: body mass index, PHS: Public Health Service, CMV: cytomegalovirus, WBC: white blood cell, CTAP: computed tomography of abdomen and pelvis, BPH: benign prostatic hyperplasia  |

**DISCLOSURE:**

The authors have no conflicts of interest to disclose.

**FUNDING/SUPPORT:**

The authors have no relevant financial relationships or in-kind support to disclose.

**RECEIVED:** March 2, 2021

**REVISION RECEIVED:** April 20, 2021

**ACCEPTED FOR PUBLICATION:** June 22, 2021

**To Cite:** Brooks AL, Jureller M, Muhdi NA, et al. Intraperitoneal Bladder Rupture in the Postrenal Transplant Period. *ACS Case Reviews in Surgery*. 2024;4(5):5-9.

## Case Description

A 64-year-old patient with a past medical history of coronavirus disease 2019 (COVID-19) pneumonia, cardiomyopathy, hypertension, and kidney stones was diagnosed with end-stage renal disease due to hypertensive nephrosclerosis. The patient had been receiving 0.4 mg of tamsulosin (Flomax®, Boehringer Ingelheim) once per day for the last seven years, and his last three prostate-specific antigen (PSA) levels were (in chronologic order): 1.7 ng/mL, 3.1 ng/mL, and 4.0 ng/mL. The patient was treated with hemodialysis from 2014 to 2020.

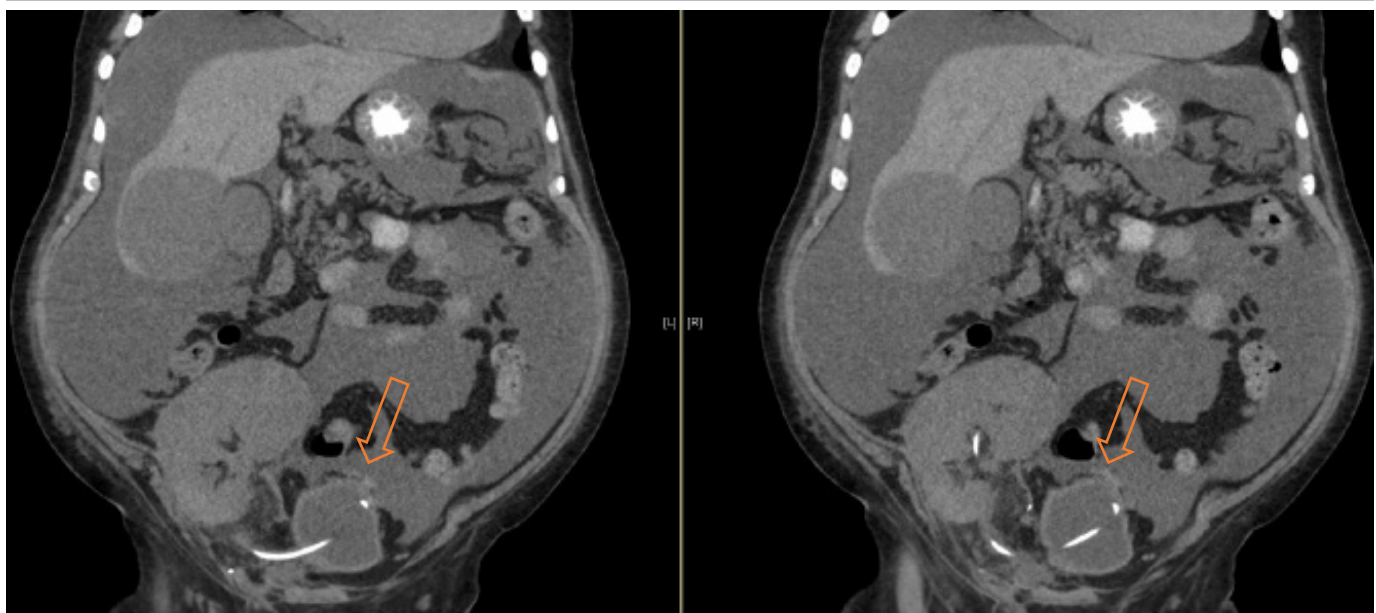
The patient underwent an uneventful left deceased-donor renal transplant from a brain death donor who was a 50-year-old female with 77% kidney donor profile index (KDPI), body mass index (BMI): 45.6 kg/m<sup>2</sup>, blood type A1, Public Health Service (PHS) increased risk, cytomegalovirus (CMV) positive and cause of death due to a stroke. The kidney was pumped until back-table preparation. A Lich-Gregoir ureteroneocystostomy was performed, with a double-J stent inserted due to the patient's very small and thick-walled bladder resulting from six years of anuria. The patient received a basiliximab (Simulect®, Novartis) induction, followed by standard immunosuppression consisting of tacrolimus (Prograf®, Astellas Pharma US, Incorporated), mycophenolate mofetil (CellCept®, Genentech), and prednisone (Deltasone®, Geneyork Pharmaceutical). CMV prophylaxis treatment was administered using valganciclovir (Valcyte®, Genentech).

The postoperative course was remarkable for delayed graft function. His foley was removed five days postoperatively and not replaced during the hospital stay. Due to COVID-19 restrictions mandating hospitalization for all dialysis-dependent transplant patients, he was discharged ten days later. On the day of discharge, his urinary output had improved to 1.6 liters in 24 hours. Laboratory results on discharge day showed a white blood cell (WBC) count of 6900/mL, hemoglobin level of 8.9g/dL, hematocrit of 27.9%, and creatinine level of 8.73 mEq/L.

He was seen in the clinic two days after discharge on postoperative day 12 and was doing well with good urinary output.

On postoperative day 16, the patient presented to the emergency department complaining of abdominal distension, nausea, vomiting, and inability to urinate for the past two days. He reported no trauma at home and his vital signs were within normal range. Physical examination revealed diffuse abdominal tenderness and guarding. Laboratory results showed elevated creatinine (11.03 mEq/L), WBC count (13,500/mL), and a CMV IgM level <30 U/mL. Notably, the patient had not undergone a dedicated bladder scan since discharge, despite experiencing delayed graft function (DGF) and oliguria. Upon admission, a CT abdomen and pelvis (CTAP) without IV contrast revealed a significant amount of free fluid in the abdomen (Figure 1), leading to a presumptive diagnosis of peritonitis secondary to a urinary leak.

**Figure 1.** CT Scan on Admission Showing Free Intraoperative Fluid. Published with Permission



The kidney transplant graft, ureteral stent, and bladder can be appreciated. The arrow indicates where the bladder perforation was found; in retrospect, a clot was in that area (found during laparoscopy).

The patient was taken back to the operating room for a retroperitoneal kidney graft exploration through the same transplant incision. The kidney graft appeared well perfused in its entirety, methylene blue dye was instilled in the bladder, and the ureteroneocystostomy anastomosis was intact without leakage. The peritoneum was also intact and bulging into the field due to intraperitoneal fluid, raising concerns for an intraperitoneal process unrelated to the transplant. Therefore, a diagnostic laparoscopy was conducted, revealing significant amounts of blood-free fluid and a clot on the peritoneal wall adjacent to the bladder (between the lateral ligaments). Upon removal of the clot, a defect in the bladder wall was identified, with leakage of methylene blue into the peritoneal cavity confirming bladder perforation (Figure 2). The laparoscope was passed through the defect into the bladder, revealing the presence of a ureteral stent and an intact ureteroneocystostomy. The defect was repaired using a continuous 3.0 V Loc suture, and a drain was inserted. The patient was discharged after

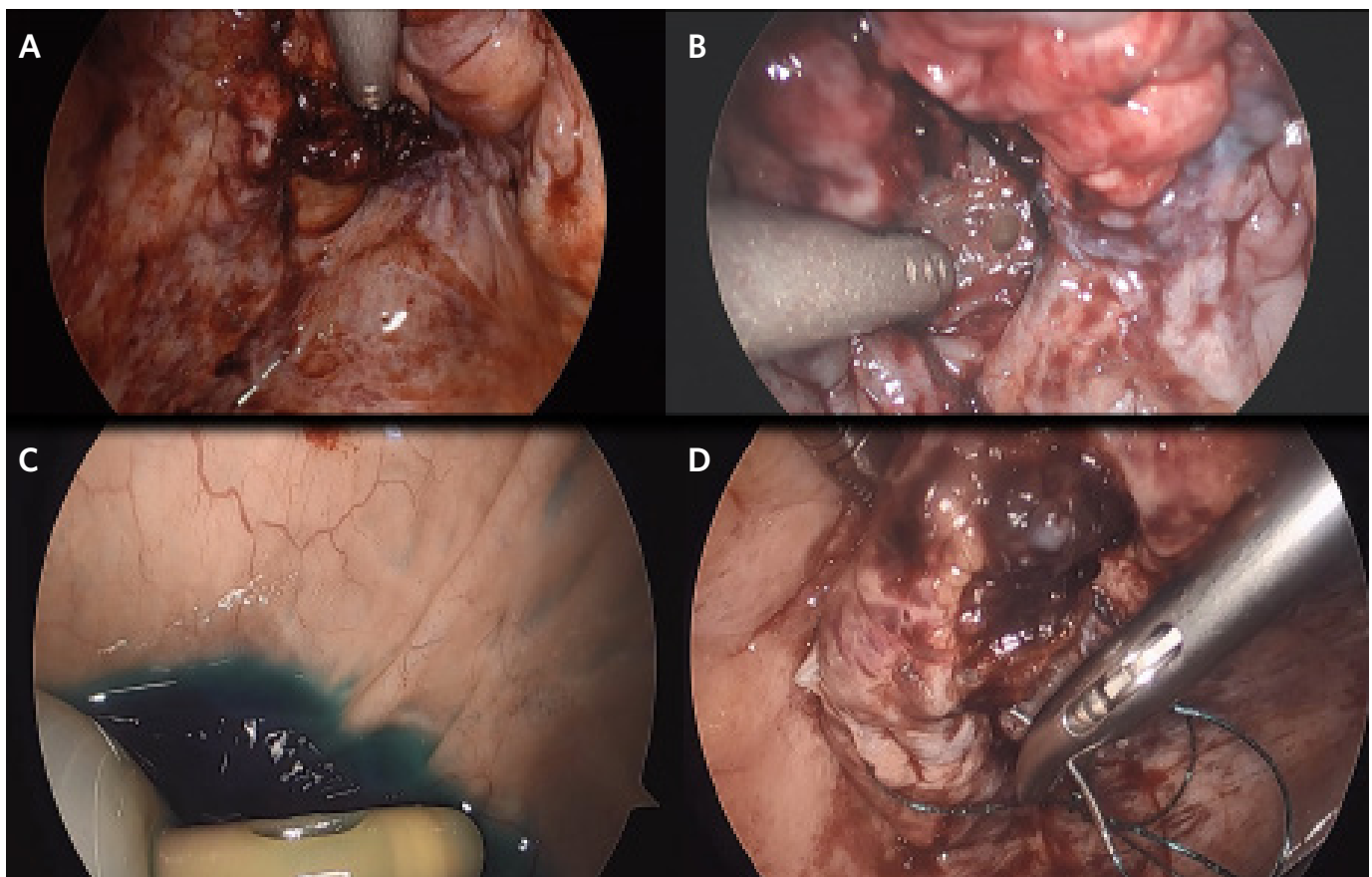
eight days. Laboratory tests at discharge showed a white blood cell count of 8100/mL, hemoglobin of 9.3g/dL, hematocrit of 30%, and creatinine of 1.77 mEq/L.

## Discussion

Urologic complications following renal transplantation have an incidence rate reported between 10% and 12.5% but remain an important contributor to morbidity and mortality.<sup>1,2</sup> There have been two reported cases of bladder rupture postrenal transplant, which described extraperitoneal bladder rupture in the immediate postrenal transplant period,<sup>3</sup> and spontaneous bladder rupture in the recipient of a transplanted kidney infected with CMV infection.<sup>4</sup>

In order to rupture a normal bladder, a pressure of at least 300 cm H<sub>2</sub>O is required.<sup>5</sup> The most common way to rupture the bladder is due to trauma causing a direct blow to a distended organ. When trauma is not the root cause,

**Figure 2.** Diagnostic Laparoscopy. Published with Permission



A) During laparoscopic exploration, a clot was found on the intraperitoneal bladder wall, positioned away from the transplant anastomosis. B) Following clot removal, a muscular defect and perforated bladder mucosa were observed. C) A laparoscope was inserted into the bladder to examine the remaining bladder mucosa. D) The bladder defect was closed using an intracorporeal running barbed suture.

bladder rupture is commonly associated with pathologies that cause overdistension and lead the bladder to rupture spontaneously.

In our case, we found no definitive causative factor for the bladder rupture, but we considered the most likely causes. Possible causes for the bladder rupture include trauma from traction or cautery during the transplant procedure, trauma from the stent, CMV cystitis, and overdistension from BPH. Trauma during the initial transplant operation is a potential cause of the perforation. However, during the initial surgery, the peritoneal space was not violated and remained fully intact. We initially opted for an open approach through the original incision and observed an intact peritoneum without urine in the retroperitoneal space. Based on this observation, we decided to switch to a laparoscopic exploration of the peritoneal cavity. During this exploration, we discovered a significant amount of fluid in the peritoneal cavity and identified a midline perforation in the bladder located between the lateral ligaments. Figure 2 illustrates the distance of the rupture from the surgical site, suggesting that it is less likely to have been caused by cautery or blunt dissection injury. Consequently, we believe that trauma during surgery is less probable.

Secondly, we considered trauma from the stent as a cause for bladder rupture. Placement of ureteral stents can have varying degrees of difficulty depending on the condition of the bladder and ureter. Overall, more atrophic bladders and narrower ureter diameters create a more challenging stent placement. In this case, the bladder was atrophic, which could lead to difficulty with stent placement. Ureteral stenting at the time of transplantation is common in many transplant centers to prevent urologic complications. While some studies have suggested that routine stent insertion decreases the incidence of postoperative urologic complications, others showed no significant improvement from stenting, highlighting an increased incidence of associated urinary tract infection, persistent hematuria, bladder discomfort, and complications during stent removal.<sup>6-11</sup> Since the stent was not found intraperitoneal, it seems less likely that stent trauma was the cause of the bladder rupture.

Another important cause of bladder rupture in the peritransplant period is CMV cystitis. While CMV is the most common viral infection contracted after renal transplantation, invasive CMV cystitis has only been reported a few times.<sup>12,13</sup> Upon return to the operating room, the patient was afebrile, received CMV prophylaxis, and had minimal

CMV serum markers. While CMV cystitis could have led to the bladder rupture, the clinical and laboratory evidence indicates that another cause is more likely.

Lastly, we considered spontaneous bladder rupture as the patient reported being unable to void well for two days prior to readmission. Spontaneous bladder ruptures occur without any precipitating trauma and are associated with diverticular disease, bladder malignancy, post-radiation injury, and ureterovesical stones, among other causes.<sup>14</sup> In our case, the patient developed an atrophic bladder due to being in an anuric state for six years. We suspect that the combination of his atrophic bladder and the gradual resumption of urine production after discharge (following foley removal) in the presence of bladder outlet obstruction (such as BPH, diverticular disease, or intrinsic bladder dysfunction) may have resulted in increased pressure, ultimately leading to spontaneous bladder rupture.

## Conclusion

Bladder rupture is a rare complication of postrenal transplant. This case of intraperitoneal bladder rupture presenting 16 days following the patient's transplant surgery highlights the need to suspect bladder rupture in patients with a history of bladder outlet obstruction prior to transplant as well as the successful use of laparoscopic technique to repair intraperitoneal bladder rupture.

## Lessons Learned

Bladder outlet obstruction increases the risk of spontaneous bladder rupture. Rare complications like bladder rupture following renal transplant are possible and should be suspected in patients with known bladder outlet obstruction. Surveillance for peritoneal signs of intraperitoneal bladder rupture is critical; our patient presented 16 days following renal transplant.

## References

1. Dalgic A, Boyvat F, Karakayali H, Moray G, Emiroglu R, Haberal M. Urologic complications in 1523 renal transplantations: The Baskent University experience. *Transplant Proc.* 2006;38(2):543-547. doi:10.1016/j.transproceed.2005.12.116
2. Yigit B, Tellioglu G, Berber I, et al. Surgical treatment of urologic complications after renal transplantation. *Transplant Proc.* 2008;40(1):202-204. doi:10.1016/j.transproceed.2007.11.024

3. Kim IY, Lee SB, Choi BK, et al. Bladder rupture in immediate postrenal transplant period of uncertain cause. *Exp Clin Transplant*. 2012;10(2):180-182. doi:10.6002/ect.2011.0089
4. Davis JL 3rd, Callender CO. Spontaneous bladder rupture and cytomegalovirus infection complicating renal transplantation: cause or coincidence?. *J Natl Med Assoc*. 1982;74(11):1131-1135.
5. Agarwal MM, Singh SK, Naja V, Mavuduru R, Mandal AK. Spontaneous bladder rupture: a diagnostic and treatment dilemma case studies and literature review. *UroToday Int J*. 2009;2(2).
6. Friedersdorff F, Weinberger S, Biernath N, Plage H, Cash H, El-Bandar N. The Ureter in the Kidney Transplant Setting: Ureteroneocystostomy Surgical Options, Double-J Stent Considerations and Management of Related Complications. *Curr Urol Rep*. 2020;21(1):3. Published 2020 Jan 18. doi:10.1007/s11934-020-0956-7
7. Harza M, Baston C, Preda A, et al. Impact of ureteral stenting on urological complications after kidney transplantation surgery: a single-center experience. *Transplant Proc*. 2014;46(10):3459-3462. doi:10.1016/j.transproceed.2014.08.051
8. Vogel T, Utech M, Schmidt F, et al. Double-J Versus External Ureteral Stents in Kidney Transplantation: A Retrospective Analysis. *Nephrourol Mon*. 2015;7(4):e27820. Published 2015 Jul 29. doi:10.5812/numonthly.27820
9. Wilson CH, Rix DA, Manas DM. Routine intraoperative ureteric stenting for kidney transplant recipients. *Cochrane Database Syst Rev*. 2013;(6):CD004925. Published 2013 Jun 17. doi:10.1002/14651858.CD004925.pub3
10. Mangus RS, Haag BW. Stented versus nonstented extravesical ureteroneocystostomy in renal transplantation: a metaanalysis. *Am J Transplant*. 2004;4(11):1889-1896. doi:10.1111/j.1600-6143.2004.00595.x
11. Sinangil A, Celik V, Barlas S, Akin EB, Ecder T. Should transplant ureter be stented routinely or not?. *Eur Rev Med Pharmacol Sci*. 2014;18(23):3551-3556.
12. Ardalan M. Rare presentations of cytomegalovirus infection in renal allograft recipients. *Nephrourol Mon*. 2012;4(2):431-436. doi:10.5812/numonthly.1844
13. Ersan S, Yorukoglu K, Sert M, et al. Unusual case of severe late-onset cytomegalovirus-induced hemorrhagic cystitis and ureteritis in a renal transplant patient. *Ren Fail*. 2012;34(2):247-250. doi:10.3109/0886022X.2011.647209
14. Saleem MA, Mahmoud AM, Gopinath BR. Spontaneous urinary bladder rupture: a rare differential for lower abdominal pain in a female patient. *Singapore Med J*. 2009;50(12):e410-e411.