

The “No-Zone” Approach to Penetrating Neck Trauma

AUTHORS:

Ryan B. Fransman MD^a; Faris K. Azar MD^a;
William Mallon, MD^a; Abhinav Nalluri, BS^b;
Joseph V. Sakran, MD, MPH, MPA^a; Elliott R. Haut,
MD, PhD^a

CORRESPONDENCE AUTHOR:

Elliott R. Haut, MD, PhD, FACS
Department of Surgery, The Johns Hopkins
University School of Medicine, Baltimore, MD
Electronic address: ehaut1@jhmi.edu.
Tel: 410-502-3122
Postal: 1800 Orleans St, Zayed 6107c, Baltimore,
MD 21287

AUTHOR AFFILIATIONS:

a. Department of Surgery, The Johns Hopkins
Hospital, Baltimore, MD
b. Johns Hopkins University School of Medicine,
Baltimore, MD

Background	Rapid and accurate management for penetrating neck trauma is crucial to preventing the high potential morbidity and mortality associated with these injuries. The current optimal evaluation and treatment algorithms are a moving target. With the advent of high resolution cross-sectional imaging, a “no zone” approach to penetrating neck trauma is becoming accepted.
Summary	We report a case of 35-year-old male presenting with a stab wound and embedded foreign body in zone three of the neck. Our patient was considered stable and a CT was obtained in order to better plan the surgical approach. The neck was opened via a partial collar incision and after identification of the major structures, the foreign body was removed. The patient was extubated the next day and was discharged on the third hospital day.
Conclusion	This case highlights the advantages of the “no zone” approach to penetrating neck injury, which is becoming a more popular management strategy. It provides an accurate assessment of the injury leading to more appropriate treatment.
Keywords	Penetrating Neck Injury, Surgical neck zones, CT angiography, Neck exploration, trauma, penetrating trauma

DISCLOSURES STATEMENT:

The authors whose names are listed immediately above certify that they have NO affiliations with or involvement in any organization or entity with any financial interest (such as honoraria; educational grants; participation in speakers' bureaus; membership, employment, consultancies, stock ownership, or other equity interest; and expert testimony or patent-licensing arrangements), or non-financial interest (such as personal or professional relationships, affiliations, knowledge or beliefs) in the subject matter or materials discussed in this manuscript.

To Cite: Fransman RB, Azar FK, Mallon W, Nalluri A, Sakran JV, Haut ER The “No-Zone” Approach to Penetrating Neck Trauma. ACS Case Reviews in Surgery. 2018;1(4):32-35.

Case Description

A 35-year-old male presented to a trauma center with a foreign body protruding from the posterior-lateral neck (zone III) causing significant deformity anteriorly towards the belly of the sternocleidomastoid (Figure 1).

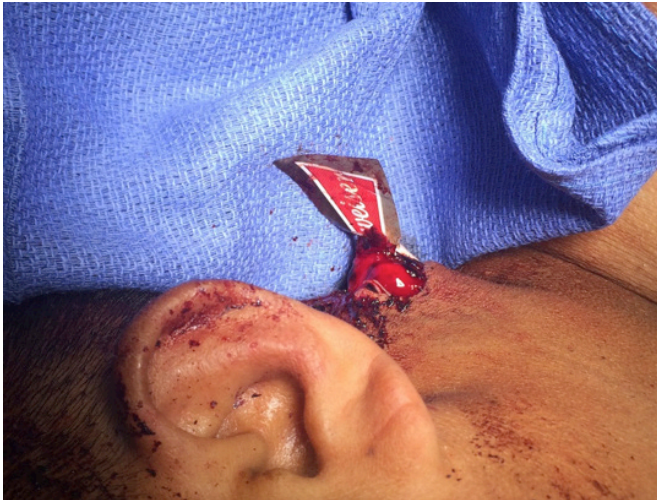

Figure 1. Foreign body protruding through left lateral neck zone 2.

On arrival, the patient was talking and protecting his airway. He was tachycardic with a heart rate of 140 bpm. He was hypotensive with systolic blood pressure of 70 mmHg. His Glasgow Coma Scale was 9. The patient was resuscitated according to Advanced Trauma Life Support protocol with blood products as well as minimal crystalloid with the assumption that the patient had bled significantly on scene. The patient responded appropriately to minimal volume resuscitation evidenced by the stabilization of his vital signs. He was intoxicated, agitated and deemed to be a threat to himself and others, and was therefore intubated. Removal of the foreign body was thought to be best suited in the operating room in a well-controlled environment based on the abutment of the object to the surrounding vascular and nervous structures as well as to ensure the retrieval of all foreign material. It is also important to note the need for personal protection and safety of the surgical team members when dealing with sharp foreign bodies and therefore this controlled environment would be optimum. Given that he became hemodynamically stable with minimal volume resuscitation, he was taken for a CT angiogram (Figure 2 and Figure 3), which revealed the distal tip of a glass beer bottle closely approximating the postero-lateral internal jugular vein without evident extravasation and no evidence of trauma to any other surrounding vasculature. The foreign body extended through the antero-medial aspect of the left sternocleidomastoid muscle and entered the left posterolateral paraspinal musculature.

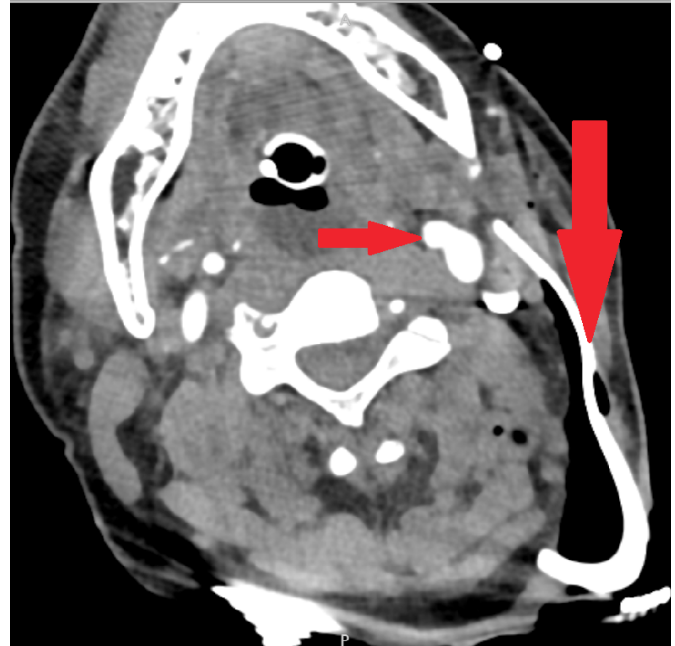


Figure 2. CT angiography of the head and neck demonstrating foreign body abutting major vasculature.

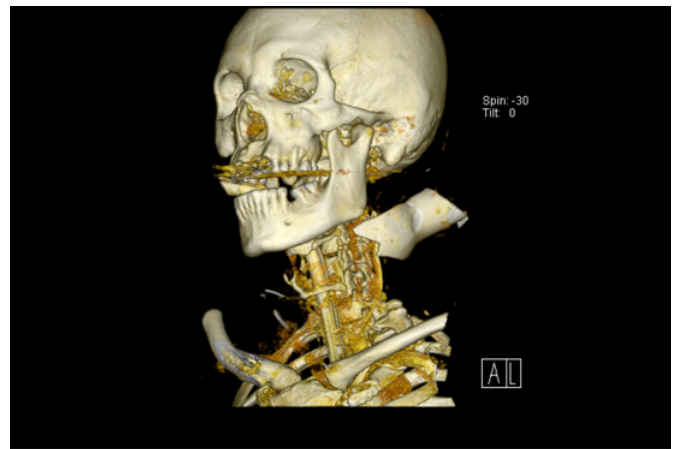


Figure 3. CT 3 dimensional reconstruction.

The patient was taken to the operating room and a partial collar incision (Figure 4) was made on the left side.

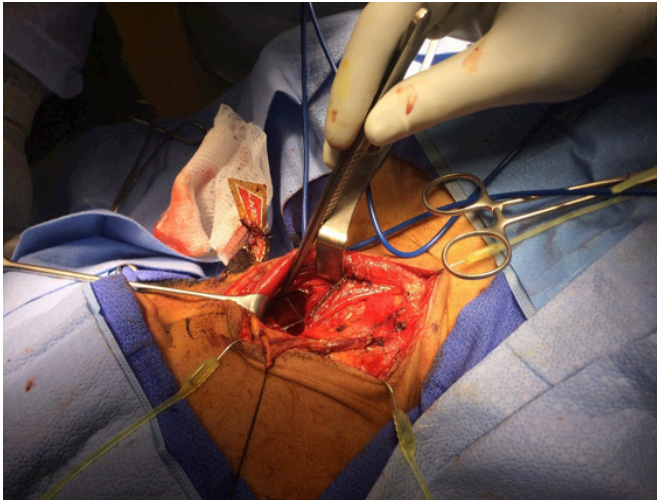


Figure 4. Collar incision exploration of the left lateral neck exposing the anatomy in relation to the foreign body.

Platysmal flaps were raised to expose the sternocleidomastoid. The external jugular vein was found to be injured and therefore ligated. The carotid sheath was explored down to the area where the glass had transected through the muscle. The internal jugular vein at this location was intact. Cranial nerve XI was not clearly identified, but when the wound through the sternocleidomastoid was inspected, there was no evidence of a transected nerve, providing assurance that the nerve was intact. A 10-cm glass foreign body was removed, with a few remaining pieces of small glass that had to be irrigated out. Hemostasis down through the skin, subcutaneous tissue, and muscle belly was achieved with electrocautery and direct pressure. The wound was closed over two closed-suction drains with staples approximating the skin. The patient was taken to the intensive care unit post-operatively. In total, the patient received 5 units of blood and had minimal blood loss during the case. The patient was extubated the following morning and transferred to the surgical ward where he was neurologically intact and progressively improved.

The foreign body measured 10.0 cm x 5.0 cm x 2.5 cm and was a portion of a glass bottle (Figure 5). He was discharged 3 days after the initial trauma and scheduled for outpatient follow-up with the trauma service.

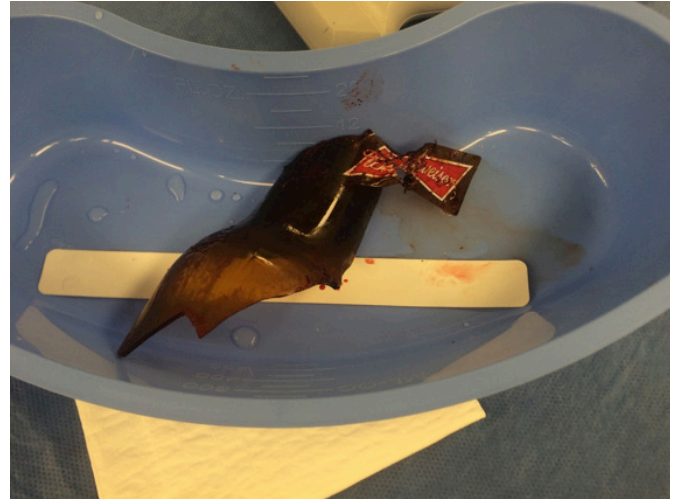


Figure 5. Foreign body pathology specimen.

Discussion

Penetrating injury to the neck is a serious and potentially life threatening injury. These injuries put patients at risk for decompensation during the first key steps of the Advanced Trauma Life Support approach to trauma: Airway, Breathing, Circulation, Disability. In today's clinical practice there is still the widespread utilization of the classical "zone" approach to characterizing the injury to the neck. This approach divided the neck into three regions and was used to help determine the next steps in management. Zone one and three injuries led to the use of endoscopy and angiography with zone two injuries requiring mandatory surgical neck exploration. In our case, there was a clear injury to zone three, the use of the step-wise zone approach to neck trauma was utilized and complimented by CT angiography once the patient was assessed to be hemodynamically stable and followed closely by surgery for foreign body removal rather than the initial described approach of initial angiography.¹

Zone three injuries are demarcated by the angle of the mandible to the skull base containing trachea, esophagus, jugular veins, carotid arteries, vertebral arteries, cranial nerves IX-XII and spinal cord. A patient presenting with a penetrating neck injury is assessed in the trauma bay as being hemodynamically stable or unstable. Furthermore, these stable patients are classified as being symptomatic or asymptomatic. All unstable patients no matter to what zone the injury is localized are taken to the operating room for surgical neck exploration. The hemodynamically stable

patients with an isolated injury whether symptomatic or not can be managed with initial evaluation by CT of the neck and chest which drives selective non-operative management.

Historically, a protocol for mandatory neck exploration of any penetrating neck trauma was advocated, given the cost of missing a critical injury is high. However, this was shown to be inefficient since more than half of explorations resulted in no major injury found.² Guidelines now suggest selective nonoperative management as an appropriate treatment pathway.³

Currently for surgical assessment there is growing support for the “No Zone” evaluation of neck injuries as contrasted with the traditional zone method described above. Typically, as with many protocols, expert surgeons utilize them as guidelines and implement anecdotal experience with intuition when establishing an intervention course⁴. With the advent of CT angiography, hemodynamically stable patients can be evaluated with a radiographic study in combination with the standard trauma physical examination, regardless of the zone of injury thus changing the zone approach towards guiding management.

The current “no zone” algorithm for penetrating neck trauma focuses on identifying hard signs of injury and assessing patient stability rather than looking to the zone of injury for management. It has been shown that using CT angiography in a stable patient with a penetrating neck injury has led to better outcomes and is favorable in comparison to the zone approach⁵. In addition, research has demonstrated that traditional “zoning” of the neck injury is not entirely accurate since almost 20 percent of zone II injuries were shown to enter zone I or III internally⁶; however the more concerning issues are those zone I or III injuries that enter zone 2 which automatically would be considered surgical. The zone approach is still useful for helping clinicians quickly and effectively describe the anatomic location of the injury⁷.

Conclusion

The traditional classification of neck injuries based on zone gives a rapid and efficient algorithm for intervention. However, with high-resolution cross-sectional imaging, the trend is moving away from treatment algorithms based on neck zones. The utilization of imaging in conjunction with the focused trauma physical exam can provide an effective

roadmap for the trauma surgeon and help ensure the best outcome for the patient by creating a clearer indication for when invasive intervention is required. Numerous published case series and reviews have supported the utility of the “no zone approach” to penetrating neck trauma.^{9,10,11}

Lessons Learned

Penetrating neck trauma is an evolving field and while the traditional neck zones can be used as a framework for anatomic consideration, a shift toward a more patient-focused “no zone” technique is appropriate in the setting of more advanced diagnostic imaging.

References

1. Gracias VH. Computed tomography in the evaluation of penetrating neck trauma: a preliminary study. *Arch Surg*. 2001. Nov;136(11):1231-5
2. Muller R. Results of mandatory exploration for penetrating neck trauma. *World J. Surg*. 1994 Nov-Dec; 18(6):917-9
3. Tisherman SA, Bokhari F, Collier B, Cumming J, Ebert J, Holevar M, Kurek S, Leon S, Rhee P. Clinical practice guideline: penetrating zone II neck trauma. *J Trauma*. 2008 May;64(5):1392-405.
4. Grosh JD. Management of penetrating neck injuries. The controversy surrounding zone II injuries. *Surg Clin North Am*. 1991 Apr; 71(2): 267 -96
5. Shiroff AA. Penetrating neck trauma: a review of management strategies and discussion of the ‘No Zone’ approach. *The American surgeon*. 2013-01;79:23.
6. Bell RB, Osborn T, Dierks EJ, Potter BE, Long WB. Management of Penetrating Neck Injuries: A New Paradigm for Civilian Trauma. *J Oral Maxillofac Surg*. 2007 Apr;65(4):691-705.
7. Long WB. Management of Penetrating Neck Injuries: a new paradigm for civilian trauma. *J Oral Maxillofac Surg*. 2007 Apr; 65 (4): 691-705
8. Roepke C, Benjamin E, Jhun P, Herbert M. Penetrating Neck Injury: What’s In and What’s Out? *Ann Emerg Med* 2016; 67: 578-580
9. Low GM, Inaba K, Chouliaras K *et al*. The use of the anatomic ‘zones’ of the neck in the assessment of penetrating neck injury. *Am Surg* 2014; 80: 970-974.
10. Samorn P, Kritayakirana K, Sriussadaporn S, Pak-art R *et al*. Selective Management of Penetrating neck injuries using “no zone” approach. *Injury* 2015 Sep; 46(9) 1720-5
11. Ooi E, Stew B, Nowicki JL. Penetrating neck injuries: a guide to evaluation and management. *Ann R Coll Surg Engl*. 2017 Oct 19: 1-6