

The Evolution of REBOA: Successful Use of Resuscitative Endovascular Balloon Occlusion for the Management of a Spontaneous Ruptured Visceral Arterial Pseudoaneurysm

AUTHORS:

Chipman AM; Ghneim M; Morrison J; DuBose JJ; Scalea TM; Diaz JJ

CORRESPONDING AUTHOR:

Amanda M. Chipman, MD
R Adams Cowley Shock Trauma Center
University of Maryland School of Medicine
22 S. Greene Street
Baltimore, MD 21201
Phone: (412) 721-1117
Email: achipman@som.umaryland.edu

AUTHOR AFFILIATION:

R Adams Cowley Shock Trauma Center
University of Maryland Medical Center
Baltimore, MD 21201

Background	A patient with nontraumatic intraabdominal hemorrhage underwent damage control laparotomy following zone 1 resuscitative endovascular balloon occlusion of the aorta (REBOA) for temporary hemostasis.
Summary	A 60-year-old female presented to an outside facility in hypertensive crisis and subsequently developed acute onset of abdominal pain, distension, and hypotension. Workup revealed possible bleeding in the lesser sac, and attempts at gastroduodenal artery angioembolization failed. On arrival at our center, she was hemodynamically unstable, requiring active transfusion. Temporary hemorrhage control was achieved using a resuscitative endovascular balloon deployed in zone 1 of the aorta (origin of the subclavian artery to celiac). The patient was taken to the operating room for damage control laparotomy, visceral angiogram, and ligation of arterial hemorrhage at the head of the pancreas. She was hospitalized for two weeks and ultimately discharged home.
Conclusion	Noncompressible torso hemorrhage has a high incidence of mortality. The use of REBOA as an adjunct to sustain the circulation until definitive surgical or endovascular repair is achieved has been well documented in the trauma literature. While many studies have demonstrated improved survival rates with REBOA utilization in trauma patients, several reports have also promoted its usefulness in nontrauma patients. We present a case in which REBOA was used successfully to achieve temporary hemostasis for nontraumatic intraabdominal hemorrhage.
Key Words	hemorrhagic shock; nontrauma; resuscitative endovascular balloon occlusion of the aorta (REBOA)

DISCLOSURE STATEMENT:

The authors have no conflicts of interest to disclose.

RECEIVED: July 15, 2020

REVISION RECEIVED: October 31, 2020

ACCEPTED FOR PUBLICATION: November 24, 2020

FUNDING/SUPPORT:

The authors have no relevant financial relationships or in-kind support to disclose.

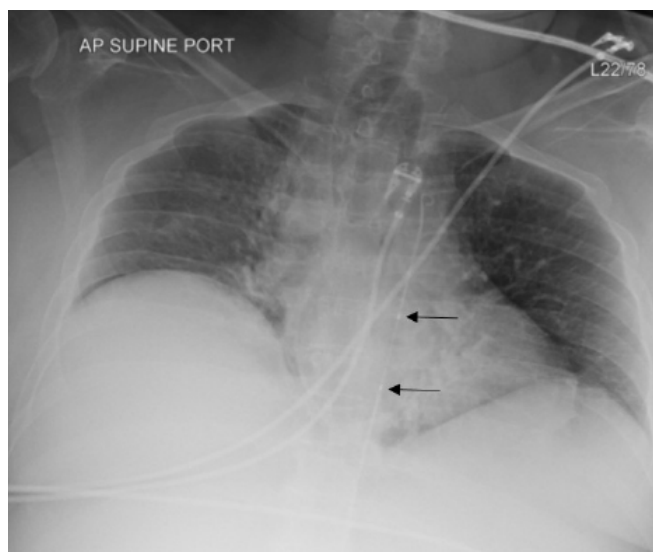
To Cite: Chipman AM, Ghneim M, Morrison J, DuBose JJ, Scalea TM, Diaz JJ. The Evolution of REBOA: Successful Use of Resuscitative Endovascular Balloon Occlusion for the Management of a Spontaneous Ruptured Visceral Arterial Pseudoaneurysm. *ACS Case Reviews in Surgery*. 2022;3(6):57-61.

Case Description

A 60-year-old female presented in hypertensive crisis, with systolic blood pressure over 200 mm Hg, to an outside facility. While in the hospital, she developed severe pain, abdominal distension, and hypotension. Computerized tomography (CT) scan revealed intraabdominal hemorrhage within the lesser sac near the head of the pancreas. She was transfused and underwent angiography by interventional radiology. No clear bleeding source was seen, but there was a blush in the lesser sac, and thus the gastroduodenal artery was coil embolized. Her hemodynamics remained labile, and she was transferred to our facility. At the outside facility, the patient received eight units of packed red blood cells (PRBC), seven units of fresh frozen plasma (FFP), and six platelets. The patient received one additional PRBC, FFP, and platelet in transport. She arrived in extremis, being actively transfused and receiving vasopressors. She received an additional five PRBCs, one FFP, and a zone 1 REBOA was placed and inflated to 10mL (Figure 1). Systemic heparin was not given due to ongoing hemorrhage.

After REBOA inflation, the patient was able to maintain a mean arterial pressure >65mm Hg, and her vasopressors were weaned off. She underwent an emergency visceral angiogram via a femoral approach from the contralateral side. Angiography revealed a ruptured pseudoaneurysm at a branch of the pancreaticoduodenal artery and a dislodgment of the previously placed gastroduodenal artery coils (Figure 2). Attempts at angioembolization were unsuccessful; therefore, an exploratory laparotomy was performed. Upon entry into the lesser sac, the REBOA was gradually released over a five-minute period as the surgical team controlled the bleeding by ligating arterial hemorrhage at the head of the pancreas. The REBOA was fully inflated for 58 minutes, and the REBOA catheter was removed after 110 minutes. The sheath was removed at the conclusion of the operation. The patient received ten PRBCs, seven FFP, two platelets, and a 450mL cell saver intraoperatively. She was initially managed with an open abdomen, and on postoperative day 2, the patient returned to the operating room for fascial closure. Postoperatively, the patient received one additional PRBC. There was very mild acute kidney injury with a peak creatinine of 1.1 (baseline 0.5) approximately 36 hours after REBOA placement. The remainder of her hospital course was uneventful.

Figure 1. Chest Radiograph Indicating Zone 1 REBOA Placement. Published with Permission



Radiopaque marker bands (arrows) denote proximal and distal margin of balloon.

Figure 2. Angiogram Imaging. Published with Permission

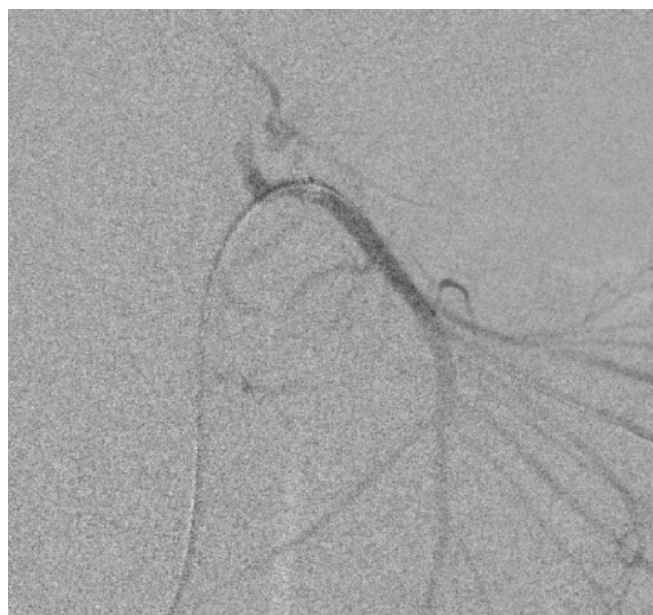

Image demonstrates bleeding off of gastroduodenal artery and in superior pancreaticoduodenal artery cascade.

Discussion

Noncompressible torso hemorrhage (NCTH) is commonly encountered after trauma, and hemorrhagic shock is a leading cause of death in both military and civilian trauma.^{1,2} About 40% of deaths are due to bleeding or its complications, and hemorrhage is the most common cause of preventable death.³ Most of these deaths are due to NCTH, with estimates as high as 70% mortality following otherwise survivable injuries.^{1,4} The advantages of aortic occlusion in the setting of NCTH have been well documented.^{5–8} Aortic occlusion during hemorrhagic shock results in increases in coronary blood flow, cardiac output, mean arterial pressure, carotid blood flow, and partial oxygen pressure of the brain.⁹

Early versions of REBOA for aortic occlusion and control of NCTH date back to the Korean War, yet due to poor outcomes and high complication rates, REBOA did not gain traction for many more years.¹⁰ However, there has been renewed interest in REBOA for the management of traumatic hemorrhage in the last decade. More modern versions of REBOA were initially used for ruptured abdominal aortic aneurysms (AAA). The utility and effectiveness of REBOA in the setting of ruptured AAA have been well-established, and thoracotomy for proximal aortic control in this setting is now rarely, if ever, utilized.^{9,11–13}

In recent years, there has been renewed interest in REBOA for trauma. Early results have shown that REBOA is a feasible method to control NCTH in patients in hemorrhagic shock and allows for more targeted aortic occlusion for pelvic, junctional, or extremity hemorrhage.^{9,14,15} Trauma patients who underwent REBOA have improved overall survival and fewer early deaths when compared to patients undergoing resuscitative thoracotomy (RT).^{9,16} Additionally, REBOA is far less invasive than RT, and complication rates have generally been low, especially with the introduction of an updated system with a smaller introducer sheath.^{17,18} Although limited data exist regarding complication rates for REBOA, prolonged ischemia followed by reperfusion can result in acute kidney injury, liver injury, intestinal ischemia, and spinal cord infarction.¹⁹ Availability of definitive hemorrhage control remains an important consideration since an increased length of time of REBOA balloon inflation is correlated with increased mortality and morbidity. Animal studies suggest zone 1 REBOA is survivable for 60 minutes and Zone 3 for 90 minutes.²⁰ In a systematic review of REBOA use, the median occlusion time for zone 1 REBOA was 63 minutes (IQR 33–88 minutes) and 45 minutes (IQR 30–105 minutes) for zone

3 REBOA.²¹ Severe complications of the lower extremities can also occur related to ischemia and vascular access complications, including pseudoaneurysm, hematoma, myonecrosis, and limb loss.²² One meta-analysis found that groin access complications for REBOA placement were approximately 4 to 5% among over 400 patients.²³ Contraindications to REBOA include bleeding proximal to the left subclavian artery and signs of bleeding in the neck, as well as in the setting of major thoracic hemorrhage or pericardial tamponade.²⁴

With the success of REBOA for traumatic NCTH, some have expanded REBOA use to nontraumatic NCTH. Approximately 2,000 deaths per year in the United States result from bleeding peptic ulcers, and hemorrhage accounts for one-quarter of maternal deaths globally. Thus, REBOA for nontraumatic NCTH represents an area for further investigation and potential reduction in mortality for these and other entities.^{25,26} Several reports have documented success when REBOA has been utilized in the setting of peripartum hemorrhage due to abnormal placentation or uterine rupture.^{27–31} REBOA has also been used with mixed results for other nontraumatic hemorrhages, including gastrointestinal (GI) bleeding and rupture of visceral aneurysms.^{21,32} One systematic review did not find any episodes of mortality among studies reporting REBOA use for GI bleeding.²¹ In a recent multi-institutional study of patients with REBOA for nontraumatic hemorrhage, 43% had REBOA placed for GI bleed, and 3% had REBOA placed for visceral artery aneurysm rupture. The overall mortality in this study was 32%. However, it is not clear what proportion of patients with GI bleeding and visceral artery aneurysm died versus other indications for nontraumatic REBOA.³³ In another small study of patients with REBOA for nontraumatic hemorrhage, approximately half of the cases were bleeding from a GI source or visceral artery aneurysm, and a similar mortality rate was reported.³²

As for trauma, the use of REBOA for nontraumatic NCTH does not represent a solution but is useful for temporary hemostasis and stabilization. It must be a part of an organized strategy to obtain long-lasting hemorrhage control either by open surgical means or by using endovascular techniques. The temporary stabilization achieved by the use of REBOA prevents cardiovascular collapse and may extend the time available to investigate multiple hemostatic approaches. Our patient represents a case in which REBOA was successfully used to achieve temporary hemostasis and hemodynamic stabilization in the setting of nontraumatic abdominal hemorrhage.

Conclusion

Noncompressible torso hemorrhage has a high incidence of mortality. While REBOA as an adjunct to sustain the circulation until definitive surgical or endovascular repair is achieved has been well documented in the trauma literature, its use in nontraumatic hemorrhage is limited but evolving. We present a case in which REBOA was used successfully to achieve temporary hemostasis for nontraumatic intraabdominal hemorrhage.

Lessons Learned

There may be a role for balloon occlusion of the aorta in nontraumatic noncompressible torso hemorrhage. Resuscitative endovascular balloon occlusion of the aorta has been used with success to stabilize patients with traumatic hemorrhagic shock. We present a case wherein this technique was successfully applied to a patient with nontraumatic abdominal hemorrhage.

References

1. Kauvar DS, Lefering R, Wade CE. Impact of hemorrhage on trauma outcome: an overview of epidemiology, clinical presentations, and therapeutic considerations. *J Trauma*. 2006;60(6 Suppl):S3-S11. doi:10.1097/01.ta.0000199961.02677.19
2. Eastridge BJ, Mabry RL, Seguin P, et al. Death on the battlefield (2001-2011): implications for the future of combat casualty care [published correction appears in *J Trauma Acute Care Surg*. 2013 Feb;74(2):706. Kotwal, Russell S [corrected to Kotwal, Russ S]]. *J Trauma Acute Care Surg*. 2012;73(6 Suppl 5):S431-S437. doi:10.1097/TA.0b013e3182755dcc
3. Curry N, Hopewell S, Dorée C, Hyde C, Brohi K, Stanworth S. The acute management of trauma hemorrhage: a systematic review of randomized controlled trials. *Cri Care*. 2011;15(2):R92. doi:10.1186/cc10096
4. Kauvar DS, Wade CE. The epidemiology and modern management of traumatic hemorrhage: US and international perspectives. *Crit Care*. 2005;9 Suppl 5(Suppl 5):S1-S9. doi:10.1186/cc3779
5. Ledgerwood AM, Kazmers M, Lucas CE. The role of thoracic aortic occlusion for massive hemoperitoneum. *J Trauma*. 1976;16(08):610-615. doi:10.1097/00005373-197608000-00004
6. Millikan JS, Moore EE. Outcome of resuscitative thoracotomy and descending aortic occlusion performed in the operating room. *J Trauma*. 1984;24(5):387-392. doi:10.1097/00005373-198405000-00003
7. Sankaran S, Lucas C, Walt AJ. Thoracic aortic clamping for prophylaxis against sudden cardiac arrest during laparotomy for acute massive hemoperitoneum. *J Trauma*. 1975;15(4):290-296. doi:10.1097/00005373-197504000-00005
8. Wiencek RG Jr, Wilson RF. Injuries to the abdominal vascular system: how much does aggressive resuscitation and prelaparotomy thoracotomy really help?. *Surgery*. 1987;102(4):731-736.
9. Moore LJ, Brenner M, Kozar RA, et al. Implementation of resuscitative endovascular balloon occlusion of the aorta as an alternative to resuscitative thoracotomy for noncompressible truncal hemorrhage. *J Trauma Acute Care Surg*. 2015;79(4):523-532. doi:10.1097/TA.0000000000000809
10. Hughes CW. Use of an intra-aortic balloon catheter: tamponade for controlling intra-abdominal hemorrhage in man. *Surgery*. 1954;36(1):65-68.
11. Malina M, Holst J. Balloon control for ruptured AAAs: when and when not to use?. *J Cardiovasc Surg (Torino)*. 2014;55(2):161-167.
12. Ten Bosch JA, Cuypers PW, van Sambeek M, Teijink JA. Current insights in endovascular repair of ruptured abdominal aortic aneurysms. *EuroIntervention*. 2011;7(7):852-858. doi:10.4244/EIJV7I7A133
13. Berland TL, Veith FJ, Cayne NS, Mehta M, Mayer D, Lachat M. Technique of supraceliac balloon control of the aorta during endovascular repair of ruptured abdominal aortic aneurysms. *J Vasc Surg*. 2013;57(1):272-275. doi:10.1016/j.jvs.2012.09.001
14. Brenner M, Teeter W, Hoehn M, et al. Use of Resuscitative Endovascular Balloon Occlusion of the Aorta for Proximal Aortic Control in Patients With Severe Hemorrhage and Arrest. *JAMA Surg*. 2018;153(2):130-135. doi:10.1001/jamasurg.2017.3549
15. DuBose JJ, Scalea TM, Brenner M, et al. The AAST prospective Aortic Occlusion for Resuscitation in Trauma and Acute Care Surgery (AORTA) registry: Data on contemporary utilization and outcomes of aortic occlusion and resuscitative balloon occlusion of the aorta (REBOA). *J Trauma Acute Care Surg*. 2016;81(3):409-419. doi:10.1097/TA.0000000000001079
16. Brenner M, Inaba K, Aiolfi A, et al. Resuscitative Endovascular Balloon Occlusion of the Aorta and Resuscitative Thoracotomy in Select Patients with Hemorrhagic Shock: Early Results from the American Association for the Surgery of Trauma's Aortic Occlusion in Resuscitation for Trauma and Acute Care Surgery Registry [published correction appears in *J Am Coll Surg*. 2018 Oct;227(4):484]. *J Am Coll Surg*. 2018;226(5):730-740. doi:10.1016/j.jamcollsurg.2018.01.044

17. Taylor JR 3rd, Harvin JA, Martin C, Holcomb JB, Moore LJ. Vascular complications from resuscitative endovascular balloon occlusion of the aorta: Life over limb?. *J Trauma Acute Care Surg.* 2017;83(1 Suppl 1):S120-S123. doi:10.1097/TA.0000000000001514
18. Teeter WA, Matsumoto J, Idoguchi K, et al. Smaller introducer sheaths for REBOA may be associated with fewer complications. *J Trauma Acute Care Surg.* 2016;81(6):1039-1045. doi:10.1097/TA.0000000000001143
19. Ribeiro Junior MAF, Feng CYD, Nguyen ATM, et al. The complications associated with Resuscitative Endovascular Balloon Occlusion of the Aorta (REBOA). *World J Emerg Surg.* 2018;13:20. Published 2018 May 11. doi:10.1186/s13017-018-0181-6
20. Doucet J, Coimbra R. REBOA: is it ready for prime time?. *J Vasc Bras.* 2017;16(1):1-3. doi:10.1590/1677-5449.030317
21. Morrison JJ, Galgon RE, Jansen JO, Cannon JW, Rasmussen TE, Eliason JL. A systematic review of the use of resuscitative endovascular balloon occlusion of the aorta in the management of hemorrhagic shock [published correction appears in *J Trauma Acute Care Surg.* 2016 Mar;80(3):554. Morrison, Jonathan James [corrected to Morrison, Jonathan J]; Jansen, Jan Olaf [corrected to Jansen, Jan O]; Rasmussen, Todd Erik [corrected to Rasmussen, Todd E]]. *J Trauma Acute Care Surg.* 2016;80(2):324-334. doi:10.1097/TA.0000000000000913
22. Bulger EM, Perina DG, Qasim Z, et al. Clinical use of resuscitative endovascular balloon occlusion of the aorta (REBOA) in civilian trauma systems in the USA, 2019: a joint statement from the American College of Surgeons Committee on Trauma, the American College of Emergency Physicians, the National Association of Emergency Medical Services Physicians and the National Association of Emergency Medical Technicians. *Trauma Surg Acute Care Open.* 2019;4(1):e000376. Published 2019 Sep 20. doi:10.1136/tsaco-2019-000376
23. Manzano Nunez R, Naranjo MP, Foianini E, et al. A meta-analysis of resuscitative endovascular balloon occlusion of the aorta (REBOA) or open aortic cross-clamping by resuscitative thoracotomy in non-compressible torso hemorrhage patients. *World J Emerg Surg.* 2017;12:30. Published 2017 Jul 14. doi:10.1186/s13017-017-0142-5
24. Borger van der Burg BLS, Kessel B, DuBose JJ, Hörer TM, Hoencamp R. Consensus on resuscitative endovascular balloon occlusion of the Aorta: A first consensus paper using a Delphi method. *Injury.* 2019;50(6):1186-1191. doi:10.1016/j.injury.2019.04.024
25. Cannon JW. Hemorrhagic Shock. *N Engl J Med.* 2018;378(4):370-379. doi:10.1056/NEJMra1705649
26. Say L, Chou D, Gemmill A, et al. Global causes of maternal death: a WHO systematic analysis. *Lancet Glob Health.* 2014;2(6):e323-e333. doi:10.1016/S2214-109X(14)70227-X
27. Manzano-Nunez R, Escobar-Vidarte ME, Orlas CP, et al. Resuscitative endovascular balloon occlusion of the aorta deployed by acute care surgeons in patients with morbidly adherent placenta: a feasible solution for two lives in peril. *World J Emerg Surg.* 2018;13:44. Published 2018 Sep 24. doi:10.1186/s13017-018-0205-2
28. Ordoñez CA, Manzano-Nunez R, Parra MW, et al. Prophylactic use of resuscitative endovascular balloon occlusion of the aorta in women with abnormal placentation: A systematic review, meta-analysis, and case series. *J Trauma Acute Care Surg.* 2018;84(5):809-818. doi:10.1097/TA.0000000000001821
29. Okada A, Nakamoto O, Komori M, Arimoto H, Rinka H, Nakamura H. Resuscitative endovascular balloon occlusion of the aorta as an adjunct for hemorrhagic shock due to uterine rupture: a case report. *Clin Case Rep.* 2017;5(10):1565-1568. Published 2017 Aug 15. doi:10.1002/ccr3.1126
30. Manzano-Nunez R, Escobar-Vidarte ME, Naranjo MP, et al. Expanding the field of acute care surgery: a systematic review of the use of resuscitative endovascular balloon occlusion of the aorta (REBOA) in cases of morbidly adherent placenta. *Eur J Trauma Emerg Surg.* 2018;44(4):519-526. doi:10.1007/s00068-017-0840-4
31. Stensaeth KH, Sovik E, Haig IN, Skomedal E, Jorgensen A. Fluoroscopy-free Resuscitative Endovascular Balloon Occlusion of the Aorta (REBOA) for controlling life threatening postpartum hemorrhage. *PLoS One.* 2017;12(3):e0174520. Published 2017 Mar 29. doi:10.1371/journal.pone.0174520
32. Hoehn MR, Hansraj NZ, Pasley AM, et al. Resuscitative endovascular balloon occlusion of the aorta for nontraumatic intra-abdominal hemorrhage. *Eur J Trauma Emerg Surg.* 2019;45(4):713-718. doi:10.1007/s00068-018-0973-0
33. Hatchimonji JS, Chipman AM, McGreevy DT, et al. Resuscitative Endovascular Balloon Occlusion of Aorta Use in Nontrauma Emergency General Surgery: A Multi-institutional Experience. *J Surg Res.* 2020;256:149-155. doi:10.1016/j.jss.2020.06.034