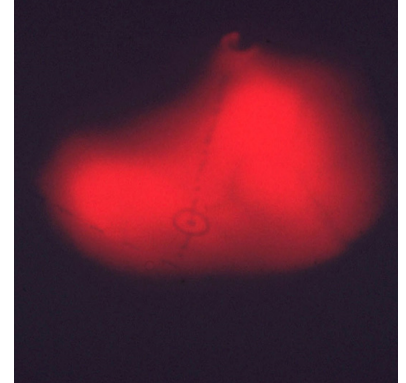

7

Following the light: A history of the percutaneous endoscopic gastrostomy tube



AMERICAN COLLEGE OF SURGEONS

Inspiring Quality:
Highest Standards, Better Outcomes

100+years

AUTHORS

Andrew T. Strong, MD¹

Jeffrey L. Ponsky, MD, FACS²

¹Department of General Surgery, Cleveland Clinic, Cleveland, OH

²Cleveland Clinic Lerner College of Medicine, Case Western Reserve University School of Medicine, Cleveland OH

CORRESPONDING AUTHOR

Andrew Strong

Department of General Surgery
Cleveland Clinic
Desk A100
9500 Euclid Avenue
Cleveland, OH 44195

In 1980 the glow of the stomach of an infant undergoing endoscopy inspired the development of percutaneous endoscopic gastrostomy (PEG), one of the most common interventions in medicine. Before then the placement of a gastrostomy required an open laparotomy, reserved mostly to support the nutritional requirements of adults with severe neurologic impairments and children with severe developmental delay. The two groups had a higher risk for general anesthesia, so an open operation solely to place a gastrostomy was seldom done.

Jeffrey Ponsky and Michael Gauderer, colleagues in surgical endoscopy and pediatric surgery in Cleveland, OH, devised a procedure to draw a tube from the mouth, down the esophagus and stomach, and out of the left upper quadrant of the abdomen. Thus no laparotomy was needed where one had always been required. PEG was among the first innovations that expanded endoscopy from a diagnostic tool for observation to a therapeutic instrument essential in the practice of gastroenterology and general surgery.



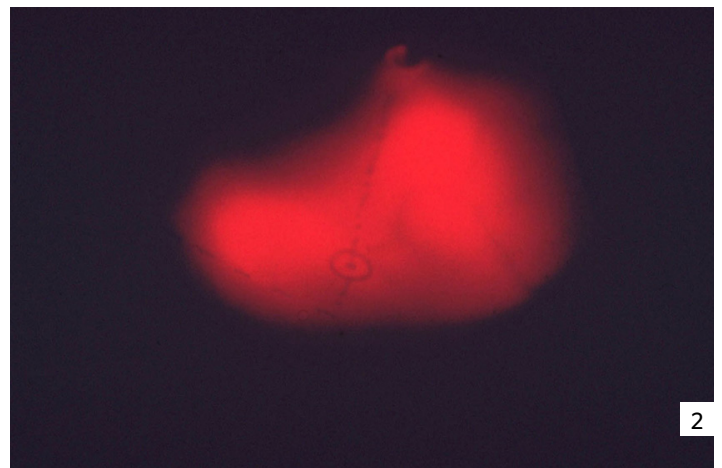
1

The glow

In 1979 two surgeons in Cleveland, OH, Jeffrey Ponsky at the University Hospital and Michael Gauderer at the Rainbow Babies and Children's Hospital (Figure 1), saw that the light from an endoscope in an infant undergoing endoscopy was visible outside the abdomen. With the stomach outlined in light, they recognized that a tube might be placed directly into the stomach from a percutaneous approach. Their insight led to an endoscopic procedure for gastrostomy, an operation heretofore restricted to open surgery. It was among the first procedures that defined minimally invasive surgery (MIS), a concept that revolutionize the field.

Fiber optic endoscopes, invented in 1960 by Basil Hirschowitz, C. Wilbur Peters, and Lawrence Curtiss at the University of Michigan, had yet not been widely applied to pediatric conditions. None of the gastroenterologists at Rainbow Hospital did the procedure, so Ponsky, then director of surgical endoscopy at University Hospital, performed endoscopy when it was needed in pediatric patients.

One was an infant under Gauderer's care. Ponsky did the procedure under anesthesia in the operating room, the lights dimmed so he could better see the image at the objective of the endoscope. Standing by, Gauderer was impressed by glow of the infant's stomach (Figure 2). It was clear there was nothing between the stomach and the abdominal wall. Their interest piqued, in a hospital corridor after the procedure Gauderer and Ponsky tried to figure out a way to use the endoscope to guide a tube into the stomach without laparotomy.



2

A new concept

They gathered the items they needed for a prototype. A flexible de Pezzar tube could be drawn through the mouth and the esophagus without trauma, but how could it pass through the walls of the stomach and the abdomen?

The crucial item was the Argyle Medicut intravenous cannula. Its shape was ideally suited to the task: a simple, conical plastic tube with a long taper that ended in a fine opening where it entered a blood vessel. It did not have a hub or side wings to help secure it to the patient's skin. Aside from the increasing diameter of the catheter, there was nothing to encumber drawing it, and the end of a de Pezzar tube behind it, out the stomach and abdomen. Ponsky and Gauderer sutured a silk thread to the tube and drew the loose ends out of the tip of the Medicut to act as a leash with which they could pull on the catheter (Figure 3).

Then a bit of endoscopic choreography was needed to pull the assembly in the desired direction. After distention of the stomach during endoscopy, a site for the gastrostomy was chosen based on the glowing silhouette of the stomach. A small incision was made in the skin and anterior sheath to allow the tube to pass more easily, through which a Medicut punctured the stomach with a quick stab under direct vision. The endoscopist grasped a silk thread passed through the lumen of the catheter and drew it out of the mouth.

The silk, once tied to the leash, was then used to draw the de Pezzar tube back down the esophagus and into the stomach. Once the tapered tip of the Medicut appeared on the surface, a steady pull with a stout clamp onto the catheter drew the rest of the Medicut and the length of the de Pezzar tube following it out of the stab incision. They added rubber cross bars to help it stay in position and keep it from being enlarged. In a period of months, they used the procedure to place gastrostomies on 12 infants and children and 19 adults.¹

Gauderer presented the procedure at the annual meeting of the American Pediatric Surgical Association, and Ponsky at the Digestive Disease Week meeting, both in May 1980. Publications followed in December and the following year.^{1,2} Over the next several years, Ponsky and his research fellows studied wound healing and maturation of the PEG tract.³

Once the concept of a minimally invasive procedure for gastrostomy was introduced, other techniques followed. As opposed to the "pull technique" developed by the Cleveland group, a "push technique" was introduced to eliminate the step of pulling the tube through the mouth and esophagus.⁴ A catheter introducer used by interventional radiologists was adapted to salvage dislodged tubes.⁵ The anchor technique


helped to ensure adequate apposition of the stomach and the anterior abdominal wall.⁶ The single lumen infusion catheter was another surgical device adopted as a PEG.⁷ The one-step gastrostomy button was an appealing, low-profile device, which is frequently used in pediatric patients.⁸ For particularly difficult cases, laparoscopic assistance was introduced as an option before laparoscopic gastrostomy become more commonplace.⁹ None of the innovations, however, matched the simplicity, utility, and safety of the original "pull technique" PEG procedure.

Significance

Easy to assemble using items found on the shelves of most hospitals, PEG had commercial potential. The market was predicted to be limited, mostly newborn infants with a small number of surgical conditions, and neurologically compromised older patients. Gauderer and Ponsky had difficulty finding a small medical device company as a partner. The numbers of procedures grew, and by 2001, 20 years after it was invented, 216,000 PEGs were done annually.¹⁰

PEG inverted the conventional view of medical progress, where an idea starts with bench research, then a disciplined clinical process of testing first in adults, then is applied with caution to children. PEG was first done on a newborn infant, after a clinician happened to notice the bright glow of a stomach during endoscopy. Application in adults came later, followed by experiments to confirm fibrous wound healing.

PEGs today continue to be commonplace on procedure schedules in endoscopy suites throughout the world. Among the first therapeutic endoscopic procedures, it helped establish the concept of the flexible endoscope as a surgical instrument. Surgical interventions based on endoscopy, such as natural orifice transluminal endoscopic surgery (NOTES), thus have roots in PEG. Therapeutic endoscopy is a clinical space shared by surgeons, gastroenterologists, and engineers. Progress in the field requires novel ideas, cooperation, and research across medical and engineering disciplines.



References

- 1 Gauderer MW, Ponsky JL, Izant RJ. Gastrostomy without laparotomy: A percutaneous endoscopic technique. *J Pediatr Surg.* 1980;15:872-875.
- 2 Ponsky JL, Gauderer MW. Percutaneous endoscopic gastrostomy: A nonoperative technique for feeding gastrostomy. *Gastrointest Endosc.* 1981;27:9-11.
- 3 Mellinger JD, Simon IB, Schlechter B, Lash RH, Ponsky JL. Tract formation following percutaneous endoscopic gastrostomy in an animal model. *Surg Endosc.* 1991;5:189-191.
- 4 Sacks BA, Vine HS, Palestrant AM, Ellison HP, Shropshire D, Lowe R. A nonoperative technique for establishment of a gastrostomy in the dog. *Invest Radiol.* 1983;18:485-487.
- 5 Russell TR, Brotman M, Norris F. Percutaneous gastrostomy. A new simplified and cost-effective technique. *Am J Surg.* 1984;148:132-137.
- 6 Wu TK, Pietrocola D, Welch HF. New method of percutaneous gastrostomy using anchoring devices. *Am J Surg.* 1987;153:230-232.
- 7 Sabnis A, Liu R, Chand B, Ponsky J. SLiC technique. A novel approach to percutaneous gastrostomy. *Surg Endosc* 2006;20:256-262.
- 8 Gauderer MW, Olsen MM, Stellato TA, Dokler ML. Feeding gastrostomy button: Experience and recommendations. *J Pediatr Surg.* 1998;23:24-28.
- 9 Edelman DS, Unger SW, Russin DR. Laparoscopic gastrostomy. *Surg Laparosc Endosc.* 1991;1:251-253.
- 10 Gauderer MWL. Percutaneous endoscopic gastrostomy—20 years later: A historical perspective. *J Pediatr Surg.* 2001;36(1):217-219.

Legends

- 1 Michael Gauderer (left) and Jeffrey Ponsky, 1981. Photo courtesy of Dr. Ponsky.
- 2 A contemporary photo of the glow from an infant abdomen illuminated from within by an endoscope.
- 3 An early version of a fully assembled PEG tube. Components included a 16 French DePezzar catheter, segments of a tubular drain acting as “T” segments to keep the tube in place, the Medicut intravenous cannula, and silk suture.