

# Blunt Cerebrovascular Injuries: Anatomic and Pathologic Heterogeneity Create Management Enigmas

Timothy C Fabian, MD, FACS

I have never spoken to such a large group, and it is rather intimidating. However, a few years ago Dr Anna Ledgerwood, the 64th Scudder Orator, told me that when you are giving a talk like this, make sure you have fun. I'm going to try to have fun and I hope you have some fun too.

Charles Locke Scudder was a surgeon-in-chief at Massachusetts General Hospital, who initiated the activities that resulted in establishment of the American College of Surgeons Committee on Trauma (COT). Dr Scudder organized the progenitor of the Committee on Trauma, the Committee on Fractures, in 1922. That committee developed the first hospital standardization manuals, which have evolved into the series of Resources for Optimal Care of the Injured Patient, which continue to this day, and they have become the cornerstone for establishment of trauma systems throughout the world. I have had the good fortune in my career to participate in the drafting of several of the manuals during my 15 years serving on the Committee on Trauma. Those experiences were fun but challenging, as Carol Williams can testify, and although at the beginning of each edition we said we would not spend an overabundance of time on word-smithing, each time we did! Dr Scudder delivered the first Oration in 1929, and the Committee on Fractures became the Committee on Trauma in the mid-1930s. I am humbled to join the list of Scudder Orators. I am sure there are several people in the auditorium today who are more deserving. I can only say that your day will come.

Before starting the Oration I must make some acknowledgments. Those of us who have achieved anything usually owe much to others. We really do "stand on the shoulders of giants." That is certainly the case with me. I started out in medical school at Loyola in the early 1970s. Dr Robert Freeark was the chairman of

our Department of Surgery, and he inspired me to pursue a career in surgery. He was a master anatomist and technician, and a very charismatic man. Then I moved onto Ohio State for surgical residency and had the good fortune to work with one of the true surgical giants of the 20th century: Dr Robert M Zollinger. He had a lot of gruffness about him but he cared deeply about the field of surgery and I cared deeply about him. He had no interest in monetary pursuits. He inspired me to go into academic surgery. Then I had the blind dumb luck to work as a trauma fellow under Dr H Harlan Stone. He was one of the premiere clinical scientists in surgery at the end of the 20th century. He was a genuine innovator and one of the first physicians to do prospective randomized trials in surgery. Drs Freeark and Stone were both Scudder Orators.

Wally Ritchie, a past executive director of the American Board of Surgery, was once asked when he was a department chairman, "Wally, who does all the work when you're out of town?" He famously replied, "The same ones who do it when I'm in town." So I, too, owe a great deal of thanks to my faculty: Drs Martin Croce, Lou Magnotti, Ben Zarzaur, Stephanie Savage, Jordan Weinberg, Tiffany Bee, Gayle Minard, Tom Schroepfel, and George Maish. They are all excellent surgeons and superb clinical investigators. Thank you for doing all the work.

As was mentioned by Dr Rotondo, Denise has been the strength of our relationship. We have been fortunate to have 5 children and 6 grandchildren. All of the people who know both of us suggest that Denise has been very long suffering and that I got the better end of the deal.

I have chosen the topic of blunt cerebrovascular injury (BCVI) because I believe it is an important clinical entity that we continue to learn more about. These represent a confusing group of injuries that lead to several quandaries in management; some produce cerebral infarcts, some are silent. Is diagnosis important, or is therapy of no consequence? For most clinical questions, we like to visualize a lot of black and white. Unfortunately, BCVI are painted with the gray brush. There are a lot of enigmas. Defining and attempting to deal with some of the

**Disclosure Information:** Nothing to disclose.

Presented at the 97th Annual Clinical Congress of the American College of Surgeons, San Francisco, CA, October 2011.

Received December 20, 2012; Accepted December 27, 2012.

From the Department of Surgery, University of Tennessee, Memphis, TN. Correspondence address: Timothy C Fabian, MD, FACS, Department of Surgery, University of Tennessee Health Science Center, 910 Madison Ave, Suite 203, Memphis, TN 38163. email: tfabian@uthsc.edu

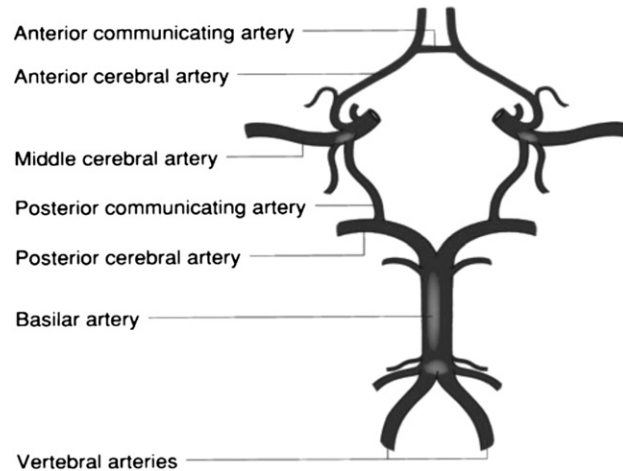
**Abbreviations and Acronyms**

BCVI = blunt cerebrovascular injury  
 CTA = computed tomography angiography  
 DSA = digital subtraction angiography  
 MRA = magnetic resonance angiography

diagnostic and therapeutic problems is the main purpose of the lecture today: to delineate the conundrums and provide some suggestions of where we go in the future. I will admit on the front end not having a lot of the answers, but on the other hand, I think I've come up with a lot of the right questions that we can address through future clinical research.

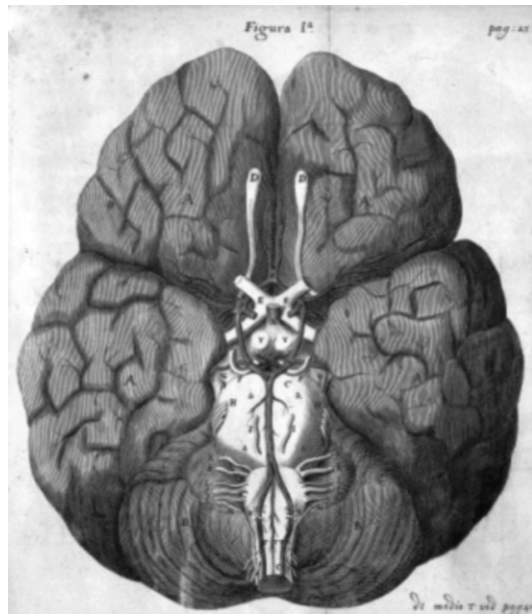
**HISTORY**

I am a history buff and think it is important that in order to know where you are going it helps to see where you've been. Let's start out with the interesting vascular structure at the base of the brain (Fig. 1). The circle of Willis provides collateral circulation for the anterior and posterior cerebral circulation. It is a critical anatomic structure that has been ignored to our peril in investigations of cerebrovascular injury. I would suggest to you it is also culprit #1 in the many enigmas surrounding BCVI. The vascular ring will serve both as a lynch pin and as a thread for lacing this talk. We will keep returning to Willis' circle, eponymously named by Richard Lower, a student and colleague of Thomas Willis. Willis



**Figure 1.** Cerebral vasculature and circle of Willis.

was a member of a group of experimental philosophers in Oxford who wrote the first major treatise on the central nervous system in 1664.<sup>1</sup> *Cerebri anatome* was written in Latin, as was nearly all of the scientific literature at the time.<sup>2</sup> There is a beautiful illustration from that treatise demonstrating the circle of Willis at the base of the pineal gland connecting the vasculature of the forebrain with that of the hindbrain (Fig. 2). Interestingly, the illustration was drawn by Sir Christopher Wren. Wren was a friend and colleague of Thomas Willis and a prominent member of the Oxford scientists of the late 17th century. But, he is more commonly



**A**



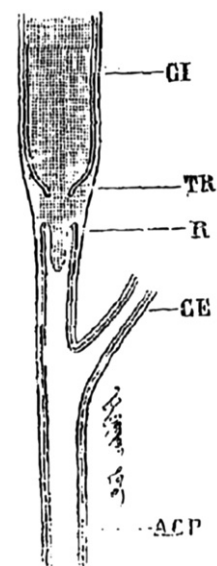
Sir Christopher Wren  
 1632 - 1723

**B**

**Figure 2.** Illustration of (A) circle of Willis by (B) Sir Christopher Wren.

known today for his brilliant architecture. After the Great Fire of London in 1666, he rebuilt 55 of the major churches including his landmark creation, St Paul's Cathedral. Although the term is generally over-used, Wren was indeed a true Renaissance man.

The first report of carotid injury was published in the *Bulletin of the National Academy of Medicine* in Paris in 1872.<sup>3</sup> Verneuil gave an account, "...a railroad worker came into the hospital with multiple contusions, violent delirium, hemiplegia, and signs of brain compression..." which led to his death 5 days later. Autopsy demonstrated "...complete rupture of the deep membrane of the left internal carotid in the neck ... obliteration of the injured vessel to the point by a clot that goes back to the last branches of the middle cerebral artery. Cerebral softening extends to nearly all of the middle lobe..." The National Academy at the time was apparently like many of our journal editors today who are quite attentive to journal impact factor that is diminished by publication of case reports. They noted, "It is not the habit of the Academy to enter such isolated observations..." such as that case report. The report contains a remarkable illustration of the pathology that was found in the railroad worker (Fig. 3). The illustration shows intimal disruption



ACP, artère carotide primitive; CE, carotide externe; CI, carotide interne; R, rupture des deux tuniques internes; TR, ces tuniques refoulées vers l'axe du vaisseau.

**Figure 3.** Illustration from Verneuil manuscript<sup>3</sup> demonstrating intimal disruption of the internal carotid artery with dissection and thrombosis.

with dissection that ultimately led to complete thrombosis. That is exactly the pathology in many of these lesions today. We first dipped our feet in this water 20 years ago in Memphis,<sup>4</sup> and I have been navigating it ever since. Truth be told, we really didn't dip our toes in the water; we more or less stumbled and fell into it. That first inquiry involved 18 cases of blunt carotid injuries: 11 unilateral, and 7 bilateral. We happened onto the diagnosis only after neurologic deterioration. We weren't astute enough to pick this lesion up at the time of admission; most of the patients came in normal neurologically and subsequently developed deficits. Some had deficits that were unexplained by CT and the diagnoses were made angiographically. Fortunately, injury recognition progressed reasonably quickly after those early observations. Over the course of the next 15 years or so, trauma center development spread throughout the country and large numbers of patients were funneled into them rather than smaller numbers being scattered far and wide. Injury patterns began becoming recognized, and screening protocols were established. Now most institutions report BCVI occurring in 1% to 2% of blunt trauma admissions.

### Anatomy and physiology

Let's now turn to the importance of anatomy and physiology in the development and progression of these lesions. There are anterior and posterior cerebral vascular distributions: the anterior through the internal carotid arteries, and the posterior through the vertebral basilar system (Fig. 1). They are joined at the base by the posterior communicating arteries through Willis' illustrious circle. Let's look more closely at the anterior and posterior circulation. The forebrain is vascularized primarily by the internal carotid arteries that originate at the midportion of the cervical vertebrae. Carotid injuries usually occur from extreme neck extension resulting in stretching of the internal carotid over C3, 4, 5. That distortion can result in the same intimal disruption demonstrated by the French railroad man (Fig. 3). Following its cervical course, the internal carotid enters the petrous portion of the temporal bone and has both a horizontal and vertical course, where it then passes into the cavernous sinus and gives off the ophthalmic artery as its first branch before continuing as the middle cerebral artery.

The blood supply to the hindbrain is provided by the vertebral basilar system, with the vertebral arteries being the first branches of the subclavian arteries. It's important to recognize that the left vertebral is dominant in two-thirds of patients. This has special relevance today in our current management of blunt aortic injuries. Most aortic injuries are now treated with endovascular stent

grafts that should ideally have a 2-cm landing zone proximal to the injury that generally occurs at the ligamentum arteriosum. In order to obtain a secure landing zone when there is a short span between the aortic tear and the left subclavian artery, some surgeons choose to land the graft proximal to and blocking the subclavian artery. I believe we are going to find that occasional cerebral infarcts develop in patients who have dominance of the left vertebral. Until branched grafts are available, it is probably judicious to avoid blocking the subclavian in the circumstance of left vertebral dominance. If blockage is unavoidable, carotid subclavian bypass should probably be entertained.

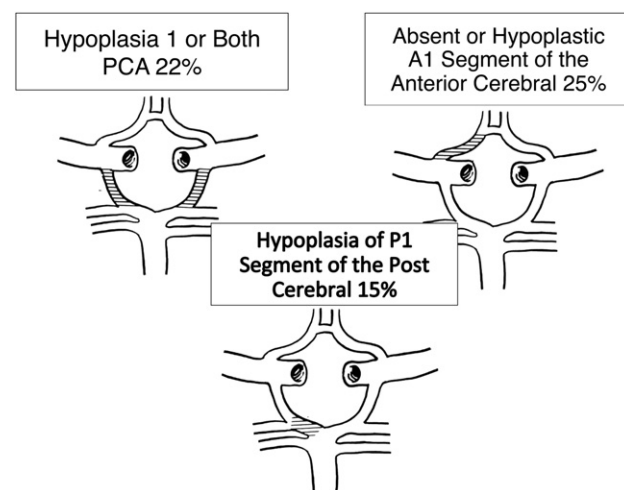
The vertebral arteries pass posteriorly and traverse the transverse foramina of C1 to C6. Not surprisingly, you might expect that fractures in that area could produce injuries to the vertebrals. On exiting the transverse foramina, the vertebral arteries enter the foramen magnum and unite to form the basilar artery and supply the structures of the hindbrain: the pons, cerebellum, and medulla.

Let's now turn to an overview of the physiology involving cerebral blood flow through these vessels. The brain is 2% of the body weight. (Well, that's not exactly true. I recently came across an autopsy series that suggested that there was a cohort in which the brain was only 1% of the body weight. And probably not surprising to this audience, it was lawyers!) The brain receives 15% of the cardiac output, and due to its high metabolic rate, consumes 25% of our oxygen. So, even short periods of ischemia can produce pronounced neurologic consequences. Considering the anterior and posterior vascular inflow, 80% is through the carotids and 20% is through the vertebrals. With that distribution in mind, one might expect to see a higher stroke rate with carotid injuries than with vertebral injuries. In a moment, we'll consider data that demonstrate that important fact. The primary cerebral collateral circulation is through the circle of Willis; secondary collaterals can develop via the ophthalmic artery to deliver blood from the external to the internal carotid circulation, and leptomeningeal branches that collateralize into the middle cerebral artery. However, although the secondary collaterals can be very important in chronic atherosclerotic cerebrovascular disease, they are probably of little significance for acute injuries.

Attention will now be turned more closely to the circle of Willis. The internal carotids enter the cavernous sinus, continue as the middle cerebral, and branch to the anterior cerebral (Fig. 1). The anterior communicating artery is the most important forebrain collateral between the right and left side. Turning to the posterior circulation,

the vertebrals combine to form the basilar artery. Unless there is a persistent remnant of the fetal circulation, the posterior cerebral arteries are terminal branches of the basilar artery. The anterior and posterior circulations are then linked through the posterior communicating artery—usually.

There are a lot of anatomic variants. This leads to the issue of the circle of Willis being the culprit responsible for some of the enigmas that we face. The circle is a key issue concerning the development of stroke. Although it is the primary collateral for the cerebral circulation, it is more accurately the most important potential collateral. Normal anatomy with a complete circle is present in only approximately 20% of the population.<sup>5</sup> Most of the variants in the other 80% are due to segmental hypoplasia or missing vessels. Variants include hypoplasia of the posterior communicators and absence or hypoplasia of either the A1 segment of the anterior cerebral or the anterior communicator (Fig. 4).<sup>5</sup> What could be the significance of absence or hypoplasia of the anterior communicating artery? If there is occlusion of the carotid artery on one side from a blunt mechanism, there is no opportunity for collateralization from the opposite side. So you would expect a high risk of stroke. However, circle of Willis variants, as they relate to outcomes, have never been considered in clinical studies of BCVI. We need to start paying attention. If there is no embolization of clot, individuals with a complete circle can probably tolerate occlusion well. Outcomes of injuries associated with hypoplastic vessels should correlate with the degree of narrowing from dissection and the degree of shock. Prevention of sustained hypotension is especially important in patients with BCVI. Shock



**Figure 4.** Variations of circle of Willis. PCA, posterior communicating artery.

will produce decreased cerebral blood flow, and in the presence of intimal disruption, lead to clot formation with either embolization or thrombosis—a fate similar to Verneuil's railroad worker from 140 years ago. He probably had an incomplete circle.

That leads us to culprit #2 concerning management enigmas—pathology of injury. As previously noted, BCVIs generally begin with arterial stretching leading to intimal disruption with exposure of subendothelial collagen and initiation of platelet aggregation (Fig. 5). Most injuries occur 1 to 2 cm beyond the carotid bifurcation and dissection can progress several centimeters. Location and extent of injury have management implications that will be considered in the discussion of therapy.

Neurologic injury develops from 2 mechanisms. Emboli can dislodge from the clot and produce stroke, or dissection can progress from the site of intimal disruption and lead to flow-significant stenosis or thrombosis. Injury sites can also deteriorate to pseudoaneurysm formation, producing a nidus for embolization. So, there are lots of ways these lesions present. We'll return to some of these issues when we consider therapy. Pathologic standardization is important in order to compare clinical studies and interpret outcomes. Credit is due to the Denver group for first defining a carotid injury grading scale that remains widely used.<sup>6</sup> Grade I consists of luminal irregularity. Grade II is a dissection with intramural hematoma or raised intimal flap. Grade III injury is pseudoaneurysm formation. Grade IV is complete occlusion. Grade V injuries consist of transection or arteriovenous fistula.

### Risk factors, screening, evolving imaging

Blunt cerebrovascular injury diagnosis and the evolving fields of screening and imaging will now be examined. It's appropriate to briefly consider the mechanics of

injury. Although rare mechanisms include common carotid injuries resulting from clothesline injury, and internal carotid injuries in children from falling with objects in their mouths, those are not what we will be concerned with today. The forces resulting from the more common mechanism of motor vehicular crashes are hyperextension and rotation described 30 years ago.<sup>7</sup> But we can't screen everyone involved in a motor vehicle crash. Besides injury grading, another important contribution came from Denver in 1999 with the first formalized screening program.<sup>8</sup> They suggested 9 injury patterns for BCVI screening: any cervical spine fracture; unexplained neurologic deficit; basilar cranial fracture into the carotid canal; Le Fort II or III fracture; cervical hematoma; cervical bruit; ischemic stroke; and head injury with Glasgow Coma Scale <6. Minor modifications have been advanced over time. Considering cohorts at risk, 2 years ago we first recognized that women were at higher risk for BCVI than men, and the risk is associated with carotid rather than vertebral arteries. Injuries occurred in 11% of screened men compared with 18% of screened women ( $p < 0.001$ ).<sup>9</sup> I assume the variance is related to sex differences in musculoskeletal structure, but it is an area that deserves greater scrutiny. Relative to adults, children seem to have the same risks for injury.<sup>10</sup>

I would like to consider an unfortunate case of BCVI that came to national attention a decade ago. It demonstrates both the mechanics as well as some of the pathophysiology that we've considered. A 13-year-old girl in attendance at a National Hockey League game was struck in the forehead by a slap shot that carried above the protective glass surrounding the rink. She was taken to an emergency room for suture of the laceration; she had a brief seizure and was admitted to the hospital. She quickly regained consciousness and was communicative and ambulatory. Two days later, she developed a high fever and lost consciousness and died. *Sports Illustrated* produced a graphic illustration of what happened to Brittanie Cecil (Fig. 6).<sup>11</sup> The impact of the 100 mph puck snapped her head back, tearing her vertebral artery. A clot developed in the artery and propagated to the point at which blood flow was inhibited. Arteriography demonstrated the injury. Clot formed at the point of intimal disruption and likely propagated up to the basilar artery. This returns us to the circle of Willis. She probably had either hypoplasia or absence of both posterior communicating arteries (Fig. 4). This eliminated any potential for collateral flow from the anterior circulation, resulting in stasis, thrombosis, and posterior fossa infarction. Could this injury have been detected in time for therapy and prevention of the lethal outcome?

#### Pathophysiology of Injury –Culprit number two

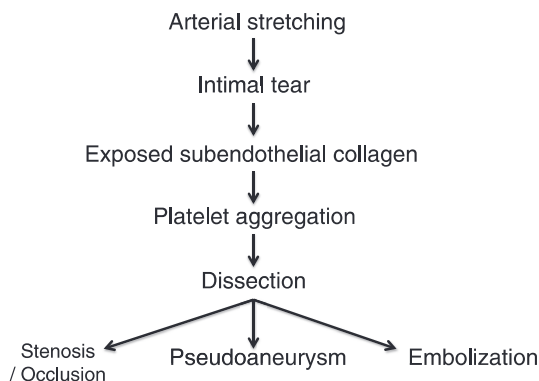
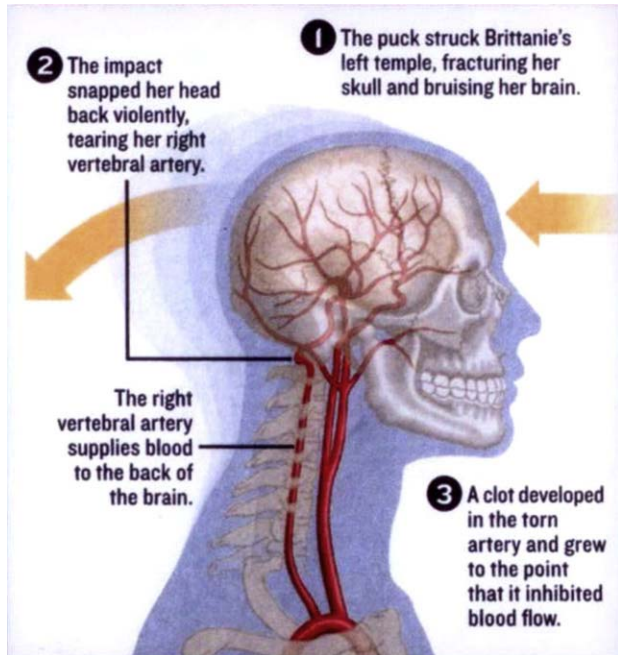


Figure 5. Pathophysiology of injury.



**Figure 6.** Vertebral artery injury from being struck in the forehead. (Reprinted with permission from: Wertheim LJ. The death of a fan. *Sports Illustrated*; Volume 96. April 01, 2002. Illustration by Jason Schneidman.)

Not at that point in time, but with our greater understanding and current approaches to screening, such an injury might be discovered today.

During the decade of the 1990s and the early years of the 21st century, digital subtraction angiography (DSA) was the major diagnostic measure available. There were small experiences with ultrasound, but DSA became the “gold standard.” In considering any screening program, benefit/risk relationships need to be addressed. Benefits for DSA included accurate detection and potential prevention of ischemic neurologic insult, but the risks included procedural complications and costs. First generation helical/spiral CT was developed and CT angiography (CTA) was introduced in the late 1990s. Magnetic resonance angiography (MRA) was also introduced around that time. Everyone interested in investigations of BCVI thought it would be fantastic to be able to avoid reliance on DSA. In the early part of the last decade, we performed a prospective study of diagnostic modalities.<sup>12</sup> The specific aims were to evaluate an aggressive screening program comparing DSA with CTA and MRA, and to evaluate neurologic outcomes based on the screening program. The screening criteria were similar to the Denver criteria, and BCVI was diagnosed in 29% of the screened population. So on first glance it looked like a pretty effective program,

identifying both carotid and vertebral injuries. However, the good news ends there.

Although we had anticipated that the accuracy of the lesser invasive diagnostic modalities would approach that of DSA, we were quite disappointed when the sensitivities of both CTA and MRA were found to be only around 50%. Turning to the second aim of the study, which was to see if early diagnosis would improve neurologic outcomes, we compared the prospective study with outcomes from the previous 5 years of study (Table 1).<sup>13</sup> We found a glass half full. Good news was that we doubled the number of vertebral injuries that were diagnosed. Early vertebral diagnosis proved important for treatment because the earlier stroke rate of 14% was eliminated with aggressive screening ( $p < 0.001$ ). Bad news was that we didn't have any impact on improving the carotid stroke rate, which remained approximately 30%. The screening program was failing to find 1 in 5 carotid injuries. Strokes were occurring in patients who did not meet screening criteria, and their injuries were diagnosed only after suffering the neurologic insult. Could we improve results with carotid lesions? We continued to chase the missing 20%.

There have been revolutionary advances in CT scanning. First generation technology opened the door for nonoperative management of solid organ injuries of the liver and spleen—huge advances in trauma care. Although first generation helical scanning did nothing for BCVI, it altered dramatically the way we manage diagnosis of blunt aortic injury. Next, the advanced multidetector scanners—16, 32, and 64-channel detectors—were introduced. It was anticipated they would produce CTA that would equal DSA for the diagnosis of BCVI. In fact, a recent straw poll conducted among trauma surgeons, neurosurgeons, and radiologists reported that 60% of practitioners in North America are using CTA for screening and diagnosis of BCVI.<sup>14</sup> Only

**Table 1.** Comparison of Blunt Cerebrovascular Injury Incidence and Stroke Rates of a Prospective Study with the Previous 5-Year Experience

Injury	Prospective, 2 y <sup>12</sup>	Previous, 5 y <sup>13</sup>	p Value
Carotid			
n	27	75	
Incidence, %	0.39	0.50	0.25
Stroke, %	33	31	0.78
Vertebral			
n	49	64	
Incidence, %	0.71	0.40	0.04
Stroke, %	0	14	0.0007

**Table 2.** Patients Screened for Blunt Cerebrovascular Injury and Having Both Digital Subtraction Angiography and 32-Channel Computed Tomography Angiography (n = 684)<sup>9</sup>

Variable	Vessels, n	No injury (DSA-)		Injury (DSA+)		Sensitivity, %
		(CTA-) TN	(CTA+) FP	(CTA-) FN	(CTA+) TP	
Overall	2,736	2,552	75	53	56	51
Carotid	1,368	1,286	30	26	26	50
Vertebral	1,368	1,266	45	27	30	53

CTA, computed tomography angiography; DSA, digital subtraction angiography; FN, false negative; FP, false positive; TN, true negative; TP, true positive. (Reprinted from: DiCocco JM, Emmett KP, Fabian TC, et al. Blunt cerebrovascular injury screening with 32-channel multidetector computed tomography: more slices still don't cut it. *Ann Surg* 2011;253:444–450, with permission.)

15% continued to use the “gold standard” of DSA. Are these practice patterns evidence-based?

Let's consider the data to support those patterns. The first report of the use of 16-channel CTA generated considerable enthusiasm, including my own.<sup>15</sup> The comparison, which involved performance of both DSA and CTA in the screened population, demonstrated a sensitivity of 98% for CTA identification of BCVI. It appeared the conundrum had been resolved. However, subsequent studies were less encouraging. The next year at the American Surgical Association, the Richmond group presented data demonstrating a sensitivity of only 74%.<sup>16</sup> Their data did have a silver lining in that the results approached 100% in the second half of their 40-month experience; a radiology learning curve was suggested.<sup>16</sup> Using a 16-channel detector, the Baltimore group reported a 64% sensitivity that was essentially the same for both carotid and vertebral lesions.<sup>17</sup>

About that time, we acquired 32-channel technology. I was somewhat relieved by anticipation that the higher resolution technology would solve the problem. We initiated a large-scale prospective evaluation in which both DSA and CTA were used in each patient screened.<sup>9</sup> There were 684 cases yielding 2,736 vessels studied—1,368 carotid and 1,368 vertebral (Table 2). Quite disappointingly, the results were not any better than those from our work with the first generation CT technology: half the injuries were missed. We evaluated our data to see if the previously reported “learning curve” was duplicated. We did not get better with time. Table 3 demonstrates the sensitivity of CTA from

several studies in which both CTA and DSA were used in most patients. Overall the results are disappointing, even with advanced generation detector technology. The extant evidence does not support the previously noted BCVI diagnostic practice patterns in North America.<sup>14</sup>

At this point I would like to return to the issue of traditional screening criteria and the fact that 20% of carotid injuries fall out of the screening parameters. With the current state of technology the answer seems to reside with application of CTA as a screening tool rather than as a diagnostic tool. We evaluated 748 patients screened with BCVI.<sup>19</sup> There were 78 carotid injuries and 65 vertebral injuries identified. Fifty-nine carotid and 61 vertebral injuries were identified using traditional screening criteria. Computed tomography angiography was added for evaluation of potential head and facial injuries, and an additional 19 carotid and 4 vertebral injuries were identified that were missed by using only traditional screening criteria. I believe we may have found how to track down the majority of the elusive 20% of missed carotid injuries. Our current diagnostic approach for victims of potential multiple system injury is to obtain neck CTA on patients requiring evaluation for head, face, or cervical spine injury. So in Memphis, we have expanded the traditional BCVI screening criteria, and now rely on CTA as a screening criterion rather than using it as a screening test. Some might consider it “a pretty long run for a short leap.” But I believe that by identifying 20% more carotid injuries, and knowing that approximately 30% of

**Table 3.** Studies Comparing Computed Tomography Angiography with Conventional Angiography for Diagnosis of Blunt Cerebrovascular Injury

Study location, first author, year	Slices, n	CTA, n	Angiography, n	Sensitivity, %
Dallas, Eastman, 2006 <sup>15</sup>	16	162	146	98
Richmond, Malhotra, 2007 <sup>16</sup>	16	119	92	74
Baltimore, Sliker, 2008 <sup>17</sup>	16	77	77	64
Columbus, Goodwin, 2009 <sup>18</sup>	16, 64	158	158	29/54
Memphis, DiCocco, 2011 <sup>9</sup>	32	684	684	51

CTA, computed tomography angiography.

undiagnosed injuries will produce strokes, we are preventing severe neurologic disability and death in some young patients.

A study from Milwaukee evaluated the cost effectiveness of screening procedures.<sup>20</sup> It reported the lifetime cost of stroke is \$600,000. The authors determined that when CTA sensitivity is less than 93% or specificity is less than 81%, DSA is the most cost effective screening test. Table 3 demonstrates sensitivities in the comparative studies of CTA and DSA to be well below 93% in nearly all of the studies. Even in the series using 64-channel technology, although the numbers are small, the sensitivity was inadequate. We definitely have a way to go with CTA in order to make it a reliable diagnostic tool for diagnosing BCVI.

### Therapy

Belief that increasing early diagnosis leads to improved outcomes also implies the belief there is effective therapy. So now let's consider some of the issues surrounding therapy. It's appropriate to note that there are no controlled therapeutic trials. We know that strokes develop in 30% to 40% of untreated carotid injuries and in 10% to 15% of untreated vertebral injuries.<sup>12,20,21,19,20</sup> A consideration from the opposite direction is that a lot of untreated BCVI patients do not suffer neurologic injuries. In fact, most vertebral injuries don't lead to stroke. Let's reconsider the issues of cerebral blood flow, the circle of Willis, and vascular pathology. Eighty percent of cerebral blood flow comes from the carotid circulation and 20% from the vertebral basilar circulation. The circle of Willis is complete in only 20%, with the remainder having a wide variety of hypoplastic and missing segments. The pathology is such that some lesions lead to critical stenosis or thrombosis and some do not. All of these variables lead to difficulty in predicting neurologic outcomes.

It is helpful to consider the temporal intervals of neurologic events and how they affect overall outcomes and considerations for therapy. Ten percent to 20% of patients with carotid injuries present to the hospital already with a stroke, primarily due to arterial thrombosis. Of those who subsequently develop strokes, 25% to 50% will occur within the first 24 hours. Approximately half of strokes occur more than 24 hours after injury and a few patients will develop strokes several days to weeks later. So, there is a therapeutic window of opportunity in 80% to 90% of patients. But there are 2 important questions: First, is therapy effective? I've had a lot of people suggest to me, "It's nice that you're picking up all of these injuries, but does treatment really make a difference?" The second question, can

complications of therapy offset a potential advantage? Before moving to a consideration for controlled clinical trials let's briefly consider "clinical equipoise." The ethics of clinical research requires equipoise, the state of genuine uncertainty on the part of the investigator regarding the comparative therapeutic merits of each arm.<sup>23</sup> You have to begin with a null hypothesis—there is no decisive evidence that an intervention is effective. An ethical dilemma arises when an investigator believes that one arm is more effective. We will return to equipoise in a moment.

What are the therapeutic options for BCVI? You can't operate on many of these patients because of the location and cranial extent of the lesions. Anticoagulation has become the most commonly used treatment. There are 3 rationales for anticoagulation: prevention of thrombosis in the case of dissection; decrease in the potential for embolization; and prevention of cerebral propagation of clot with intracranial vessel occlusion. The latter event occurred in the vertebral basilar circulation in the hockey accident, and it occurs through propagation of carotid clot into the middle cerebral artery, accounting for some delayed cortical events. There certainly are contraindications to anticoagulation. But remember, heparin is not a thrombolytic agent—it prevents coagulation. Absolute contraindications include ongoing hemorrhage, impending surgery, and bleeding diatheses. Relative contraindications include intracerebral hematomas, and subdural hematomas. With cessation of hemorrhage, heparin is generally fairly safe.

Let's consider the available evidence that supports anticoagulation for treatment of BCVI. In conjunction with our neurosurgeons we began routinely using heparin in the early 1990s.<sup>24</sup> Logistic regression analysis demonstrated 2 things that were related to survival: brain injury ( $p = 0.056$ ) and the treatment with heparin ( $p = 0.015$ ). For neurologic improvement, heparin was statistically highly significant ( $p = 0.006$ ). Statistics are one thing, but I guess what was most convincing to me was when we considered 15 patients who had bilateral injuries that were treated with heparin. The asymptomatic side remained asymptomatic—I can't put a  $p$  value on it, but it's a simple observation that struck me as a clinician.

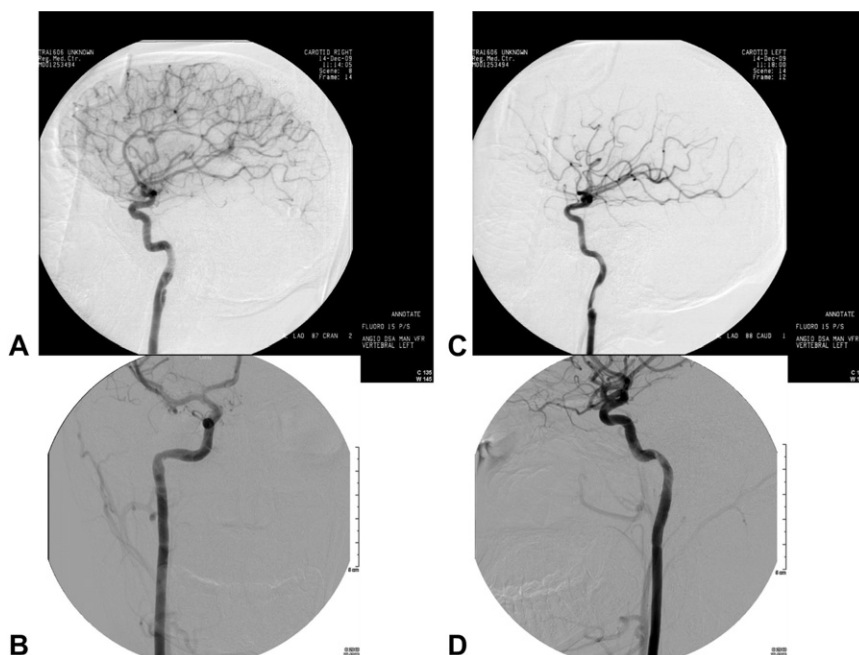
Others have arrived at similar conclusions. In Denver in 2004 heparin was deemed "the gold standard therapy for blunt carotid injuries."<sup>25</sup> What about anticoagulation vs antiplatelet therapy? A few years ago I would have thought heparin must be a lot better. Today many patients are on aspirin and clopidogrel for a wide range of cardiac and peripheral vascular indications, and we have all had substantial experience in recent years



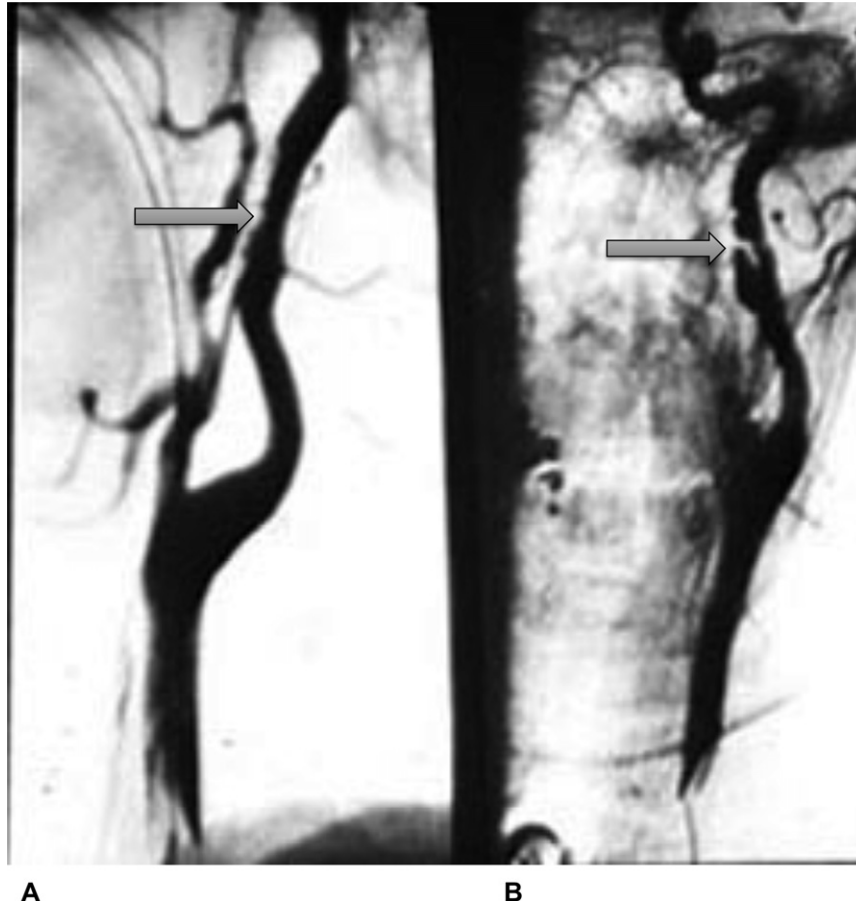with patients on antiplatelet agents requiring both emergent and elective surgery. They certainly can bleed—antiplatelet agents are quite effective. Once again, the Denver group weighed in on this and actually found equivalence of antiplatelet and anticoagulation in 282 asymptomatic patients.<sup>21</sup> They observed only 1 stroke. In cohorts that had no, or inadequate, initial treatment, they reported a 21% stroke rate. The Baltimore group also evaluated the efficacy of therapy in both carotid and vertebral injuries.<sup>22</sup> They reported on 200 arterial lesions and found a stroke rate of 26% in untreated and 4% in treated patients, and they observed a 50% mortality associated with stroke. They concluded that treatment is indeed beneficial.

All of these studies that evaluated the efficacy of treatment are retrospective and all demonstrate positive results with anticoagulation or antiplatelet therapy. Turning to the straw poll to consider what is happening in North America today, one-third of patients are treated with antiplatelets, almost half with anticoagulation, the remainder with both; nearly all patients without contraindications are being treated.<sup>14</sup> Should we conduct a prospective, randomized, controlled study for efficacy: treatment vs placebo? I would first ask, “Do we have equipoise?” A randomized, placebo-controlled trial would be difficult to conduct in light of the available data and current practice patterns.

Moving on to consideration of BCVI stenting, endovascular therapy has been used for patients with pseudoaneurysms and significant stenoses secondary to dissection. But, it is a complex issue. A case demonstrates application of carotid stenting quite well. An 18-year-old woman had bilateral injuries with a dissection and pseudoaneurysm occurring on the right, and a significant flow-limiting stenosis from dissection on the left side (Fig. 7). We'll come back to that case in a moment. The natural history of most pseudoaneurysms in the peripheral vascular circulation is that of expansion, thrombosis, or persistence with embolization; very few rupture in the carotid system. We found that of 42 dissections, follow-up DSA in 2 weeks showed deterioration to pseudoaneurysms in 12 (29%).<sup>24</sup> Unless they are quite small, pseudoaneurysms don't go away; of 6 patients who initially presented with pseudoaneurysms, 5 continued to be present on follow-up study. So overall in that series, 35% of carotid injuries ultimately resulted in pseudoaneurysm formation. To demonstrate consistency of the pathology, we'll consider a similar study from Denver.<sup>26</sup> In follow-up angiographic evaluation of 136 lesions, they likewise found that exactly 35% resulted in pseudoaneurysm formation. It is also important to recognize that even rather subtle injuries can have remarkable pathologic deterioration. Figure 8 demonstrates what was initially interpreted as a grade I injury that deteriorated to



**Figure 7.** Eighteen-year-old woman in a motor vehicle crash with bilateral carotid injury; (A) right internal carotid with dissection; (B) left internal carotid dissection with stenosis; (C and D) angiograms 10 months after bilateral carotid stents.



**Figure 8.** Blunt internal carotid injury; (A) initial arteriogram demonstrating grade I injury; (B) same injury on 2-week follow-up angiogram demonstrating deterioration to grade III injury.

significant dissection with cobbling and pseudoaneurysm formation on 2-week follow-up. These injuries can be very tricky.

The initial carotid stent study for pseudoaneurysms from Denver demonstrated good early results.<sup>27</sup> However, 5 years later they reported a larger series of 23 stented vs 23 nonstented patients, and the findings led to a retraction of the earlier stent endorsement.<sup>28</sup> With a mean follow-up of 2.4 months on 18 of the stented patients, they found only a 55% patency. That's a problem. We entered the stenting arena about the same time as our colleagues. In a study of 18 patients with a mean follow-up of 8 months, we found 100% patency.<sup>29</sup> The east Texas group has also taken a great interest in BCVI and reported an experience with carotid stents.<sup>30</sup> They stented 11 patients, including 9 who had associated intracranial hemorrhage. The patients were treated with anticoagulation and antiplatelet agents and none had progression of intracranial hemorrhage. They had follow-up of 6 months to 4 years on 7 patients.

All stents remained patent, with 1 developing a 50% stenosis treated with angioplasty. What are the differences in these 3 reports? I suspect the likely explanation lies with antiplatelet agent administration. Early on I don't believe the extreme importance of these agents was widely appreciated.

Let's consider coronary stents. With premature discontinuation of clopidogrel, there is a significant risk of thrombosis, which carries a 45% mortality rate. Two-thirds of drug-eluting stent thromboses have been related to stopping antiplatelet drugs. We are using bare metal stents rather than drug-eluting stents for carotid disease. Dual antiplatelet therapy is clearly indicated for elective carotid stenting. It prevents acute thrombosis, and is necessary until endothelialization takes place. It takes about 6 to 8 weeks for bare metal stents to endothelialize, and it is critical that patients are maintained on antiplatelet medication during that time or there will be a high rate of thrombosis. What about multiple injuries requiring secondary surgical

procedures? Those procedures should be done before carotid stenting. Holding antiplatelet agents perioperatively will produce a high rate of occlusion and stroke. Compliance with medications can be a real problem with young trauma patients. What about the price? Until recently clopidogrel (Plavix [Bristol-Myers Squibb]) patient costs were approximately \$200.00 a month—a clear disincentive for compliance. When it comes to eating vs taking Plavix, what do you think most people would do? The good news is that Plavix went off patent in the summer of 2012. That should increase compliance, but it remains imperative for us to strongly emphasize to stented patients the importance of staying on the antiplatelet regimen.

Let's return to the young lady with bilateral carotid injuries. She underwent bilateral carotid stenting and was maintained on aspirin and clopidogrel for 3 months. The follow-up angiogram at 10 months demonstrated normal appearing carotid arteries (Fig 7).

Figure 9 illustrates our recent management of 263 injuries in 222 patients.<sup>31</sup> Twenty-two (10%) sustained infarcts before diagnosis, a number similar to those in other studies that have evaluated temporal relationship of strokes in patients with BCVI. In this most recent series, approximately 70% of carotids and 25% of vertebrals were managed with endovascular therapy. Are we getting too aggressive? Perhaps. The follow-up of 85% (mean 22 months and median 17 months) was surprisingly good for trauma patients—much credit is due our residents and students. There were 6 strokes in follow-up, and 5 potential strokes; patients with associated head injuries make it difficult to determine stroke. So being conservative, we report a 9% postdiagnosis stroke rate in initially asymptomatic patients. There were 13 outpatient deaths, for an overall 17% mortality. All patients do not do well when they go home. Evaluation of strokes in the asymptomatic patients, inpatients, and follow-up demonstrated the endovascular therapy was as good as our medical therapy in both carotid and vertebral cohorts, even though the endovascular group

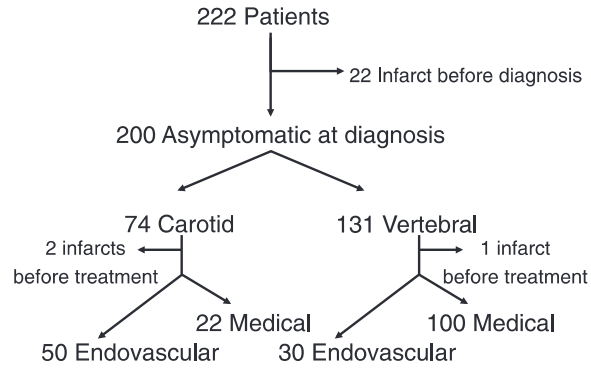


Figure 9. Algorithm demonstrating recent blunt cerebrovascular injury treatment strategy in 222 patients. (Reprinted with permission from the University of Tennessee Department of Surgery.)

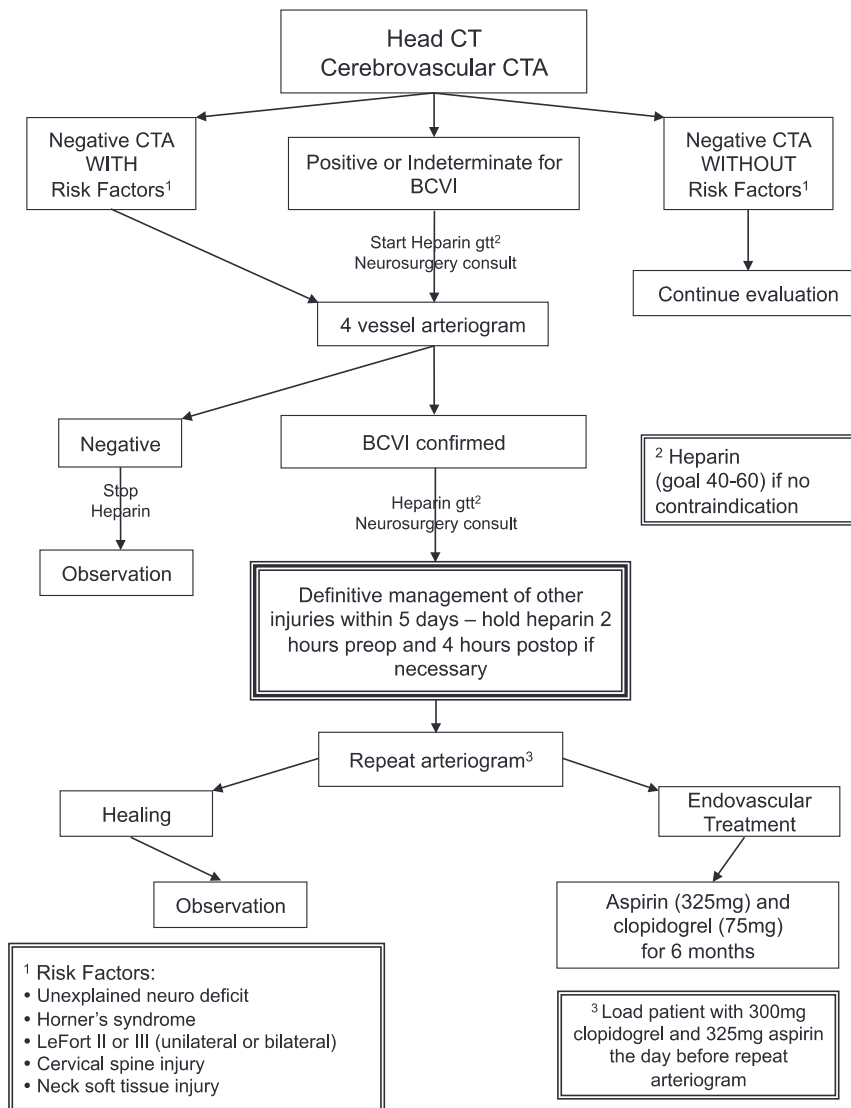
sustained higher grades of injury. Our postdiagnosis stroke rates and mortality compare quite favorably with those in other reports, especially considering that most of the other reports include only in-hospital results (Table 4).

Figure 10 demonstrates our current management algorithm developed from an evidence-based approach derived from the clinical research of our colleagues and from research in our own department. For grades I to III (dissections or pseudoaneurysms) we initiate a heparin drip with a relatively modest partial thromboplastin time goal of 40 to 60 seconds, and repeat the angiogram in 10 to 14 days. If the lesions have deteriorated, are flow-significant, or aneurysmal, most have endovascular therapy. Grade IV occlusions are usually treated with aspirin. Carotid cavernous fistulas are managed with endovascular techniques.

So where do we go from here? Many have called for prospective, randomized trials. Before we perform that important work, I think we need to do more preparative homework. I will leave you with what I think the path to the future for management of these injuries needs to be (Fig. 11). First of all, we ought to have an effective national BCVI registry—a task I plan to address. In

Table 4. Stroke Rates Associated with Blunt Internal Carotid Injury Reported in Recent Literature

Study/location, first author, year	n	Stroke post-diagnosis, %	Mortality, %
Western Trauma, Cogbill, 1994 <sup>32</sup>	49	29	33
Denver, Biffi, 2002 <sup>26</sup>	171	14	11
Denver, Cothren, 2005 <sup>28</sup>	46	11	—
Memphis, Edwards, 2007 <sup>29</sup>	110	8	26
Tyler, Berne, 2008 <sup>30</sup>	11	10	18
Baltimore, Stein, 2009 <sup>22</sup>	147	7	13
Memphis, DiCocco, 2011 <sup>31</sup>	222	4	11
Including outpatient		7–9	18



**Figure 10.** Current blunt cerebrovascular injury management algorithm (Memphis). CTA, computed tomography angiography. (Reprinted from: DiCocco JM, Fabian TC, Emmett KP, et al. Optimal outcomes for patients with blunt cerebrovascular injury [BCVI]: tailoring treatment to the lesion. *J Am Coll Surg* 2011;212:549-557, with permission from Elsevier.)

conjunction with a registry, we need to set up a clinical trials network. The data we have looked at today show there are many institutions interested in BCVI. We should start out with prospective observational studies addressing imaging. We need to get back to Thomas Willis' circle and evaluate it more routinely when evaluating outcomes in these patients. We should be looking at cerebral blood flow, possibly transcranial Doppler studies, and maybe better technology will come soon. And then, we need to look at what's happening with therapeutic outcomes. Once we get these prospective observations studies completed, which will take 3 to

5 years, hopefully we can begin some important randomized, controlled trials based on the observational studies. But, in order to accomplish any of this, it falls on all of our backs within the American College of Surgeons Committee on Trauma, the American Association for the Surgery of Trauma, and other organizations such as the National Trauma Institute, to secure established funding streams in order to do sophisticated clinical research. Effective research does not come cheaply, and we must establish a solid financial foundation.

I thank the American College of Surgeons and the Committee on Trauma for honoring me with the great

### Path to the Future

- BCVI Registry
- Clinical trials network
- Observational studies
  - Imaging
  - Cerebral blood flow
  - Therapy
- RCTs based on observations
- Establish funding streams

**Figure 11.** Path to the future. BCVI, blunt cerebrovascular injury; RCT, randomized controlled trial.

distinction of the Scudder Oration. I'll also tell Anna that I did have fun, and I hope that some of you had fun, too. Thank you very much.

### REFERENCES

1. Donaldson IML. Cerebri anatome: Thomas Willis and his circle. *J R Coll Physicians Edinb* 2010;40:277–279.
2. Willis T. Cerebri anatome, cui accessit nervorum descriptio et usus. London: James Flesher, Joseph Martyn and James Allestrey; 1664.
3. Verneuil M. Contusions multiples deire violent hemiplegie droite signes de compression cerebrale. Paris: Bull Acad Natl Med; 1872.
4. Fabian TC, George SM Jr, Croce MA, et al. Carotid artery trauma: management based on mechanism of injury. *J Trauma* 1990;30:953–963.
5. Riggs HE, Rupp C. Variation in form of circle of Willis: the relation to the variations to collateral circulation: Anatomic analysis. *Arch Neurol* 1963;8:24–30.
6. Biffi WL, Moore EE, Offner PJ, et al. Blunt carotid arterial injuries: implications of a new grading scale. *J Trauma* 1999;47:845–853.
7. Krajewski LP, Hertzner NR. Blunt carotid artery trauma: report of two cases and review of the literature. *Ann Surg* 1980;191:341–346.
8. Biffi WL, Moore EE, Offner PJ, et al. Optimizing screening for blunt cerebrovascular injuries. *Am J Surg* 1999;178:517–522.
9. DiCocco JM, Emmett KP, Fabian TC, et al. Blunt cerebrovascular injury screening with 32-channel multidetector computed tomography: more slices still don't cut it. *Ann Surg* 2011;253:444–450.
10. Kopelman TR, Beerardoni NE, O'Neill PJ, et al. Risk factors for blunt cerebrovascular injury in children: do they mimic those seen in adults? *J Trauma* 2011;71:559–564.
11. Wertheim LJ. The death of a fan, Volume 96. *Sports Illustrated*; April 01, 2002.
12. Miller PR, Fabian TC, Croce MA, et al. Prospective screening for blunt cerebrovascular injuries. Analysis of diagnostic modalities and outcomes. *Ann Surg* 2002;236:386–395.
13. Miller PR, Fabian TC, Bee TK, et al. Blunt cerebrovascular injuries: diagnosis and treatment. *J Trauma* 2001;51:279–286.
14. Harrigan MR, Weinberg JA, Peaks Y-S, et al. Management of blunt extracranial traumatic cerebrovascular injury: a multi-disciplinary survey of current practice. *World J Emerg Surg* 2011;6:11.
15. Eastman AL, Chason DP, Perez CL, et al. Computed tomographic angiography for the diagnosis of blunt cervical vascular injury: is it ready for primetime? *J Trauma* 2006;60:925–929.
16. Malhotra AK, Camacho M, Ivatury RR, et al. Computed tomographic angiography for the diagnosis of blunt carotid/vertebral artery injury. A note of caution. *Ann Surg* 2007;246:632–643.
17. Sliker CW, Shanmuganathan K, Mirvis SE. Diagnosis of blunt cerebrovascular injuries with 16-MDCT: accuracy of whole-body MDCT compared with neck MDCT angiography. *Am J Roentgenol* 2008;190:790–799.
18. Goodwin RB, Beery PR 2nd, Dorbish RJ, et al. Computed tomographic angiography versus conventional angiography for the diagnosis of blunt cerebrovascular injury in trauma patients. *J Trauma* 2009;67:1046–1050.
19. Emmett KP, Fabian TC, DiCocco JM, et al. Improving the screening criteria for blunt cerebrovascular injury: the appropriate role for computed tomography angiography. *J Trauma* 2011;70:1058–1065.
20. Kaye D, Brasel KJ, Neideen T, Weigelt JA. Screening for blunt cerebrovascular injuries is cost-effective. *J Trauma* 2011;70:1051–1057.
21. Cothren CC, Biffi WL, Moore EE, et al. Treatment for blunt cerebrovascular injuries. Equivalence of anticoagulation and antiplatelet agents. *Arch Surg* 2009;144:685–690.
22. Stein DM, Boswell S, Sliker CW, et al. Blunt cerebrovascular injuries: does treatment always matter? *J Trauma* 2009;66:132–144.
23. Freedman B. Equipoise and the ethics of clinical research. *N Engl J Med* 1987;317:141–145.
24. Fabian TC, Patton JH Jr, Croce MA, et al. Blunt carotid injury. Importance of early diagnosis and anticoagulant therapy. *Ann Surg* 1996;223:513–525.
25. Cothren CC, Moore EE, Biffi WL, et al. Anticoagulation is the gold standard therapy for blunt carotid injuries to reduce stroke rate. *Arch Surg* 2004;139:540–546.
26. Biffi WL, Ray CE Jr, Moore EE, et al. Treatment-related outcomes from blunt cerebrovascular injuries. Importance of routine follow-up arteriography. *Ann Surg* 2002;235:699–707.
27. Coldwell DM, Novak Z, Ryu RK, et al. Treatment of post-traumatic internal carotid arterial pseudoaneurysms with endovascular stents. *J Trauma* 2000;48:470–472.
28. Cothren CC, Moore EE, Ray CE Jr, et al. Carotid artery stents for blunt cerebrovascular injury. Risks exceed benefits. *Arch Surg* 2005;140:480–486.
29. Edwards NM, Fabian TC, Claridge JA, et al. Antithrombotic therapy and endovascular stents are effective treatment for blunt carotid injuries: results from long term follow-up. *J Am Coll Surg* 2007;204:1007–1015.
30. Berne JD, Reuland KR, Villarreal DH, et al. Internal carotid artery stenting for blunt carotid artery injuries with an associated pseudoaneurysm. *J Trauma* 2008;64:398–405.
31. DiCocco JM, Fabian TC, Emmett KP, et al. Optimal outcomes for patients with blunt cerebrovascular injury (BCVI): tailoring treatment to the lesion. *J Am Coll Surg* 2011;212:549–559.
32. Cogbill TH, Moore EE, Meissner M, et al. The spectrum of blunt injury to the carotid artery: a multicenter perspective. *J Trauma* 1994;37:473–479.