

A Case of Triple-Negative Breast Cancer in a Kidney Transplant Patient

AUTHORS:

Pinnock N; Higham A

CORRESPONDING AUTHOR:

Anna Higham, MD
 Carle Cancer Center/Mills Breast Cancer Institute
 509 W. University Avenue
 Urbana, IL 61801
 Email: anna.higham@carle.com

AUTHOR AFFILIATION:

Department of Surgery
 Carle Foundation Hospital
 Urbana, IL 61801

Background	A female patient with a history of deceased donor kidney transplant and on immunosuppression therapy presented with early-stage triple-negative breast cancer. She underwent breast-conserving surgery (BCS) with sentinel lymph node biopsy (SLNB).
Summary	A 73-year-old female with a past medical history of deceased-donor kidney transplant ten years prior presented for evaluation of a left breast lesion detected on routine screening mammography. Ultrasound-guided biopsy revealed a clinically T1b N0 M0 high-grade, ER/PR negative, HER2 negative left breast cancer. This case presented a challenge due to the patient's immunosuppressed status with tacrolimus and mycophenolate. Because of the patient's multiple medical comorbidities, she was not considered a good candidate for neoadjuvant chemotherapy. The patient underwent BCS with SLNB. Her pathologic stage was T1cN0M0. Adjuvant chemotherapy was attempted but not tolerated by the patient. She received daily adjuvant radiotherapy for six weeks. Postoperatively, the patient was hospitalized for urinary sepsis, which was determined to be unrelated to the surgical procedure. There are currently no signs of recurrence or systemic disease, and the patient's kidney function has fully recovered without graft rejection.
Conclusion	Breast cancer occurring in kidney transplant recipients is rare, presenting distinct treatment challenges. We share our approach in managing a female recipient with triple-negative left breast cancer. This case underscores the absence of established guidelines for surgical and medical management. Our aim is to add to the limited literature on breast cancer management in kidney transplant patients.
Key Words	breast cancer; triple-negative breast cancer; kidney transplant
Abbreviations	BCS: breast-conserving surgery, SLNB: sentinel lymph node biopsy, IDC: invasive ductal carcinoma, ER: estrogen receptor, PR: progesterone receptor, HER2: human epidermal growth factor receptor

DISCLOSURE STATEMENT:

The authors have no relevant financial relationships to disclose.

FUNDING/SUPPORT:

The authors have no relevant financial relationships or in-kind support to disclose.

RECEIVED: January 26, 2021

REVISION RECEIVED: April 29, 2021

ACCEPTED FOR PUBLICATION: June 22, 2021

To Cite: Pinnock N, Higham A. A Case of Triple-Negative Breast Cancer in a Kidney Transplant Patient. *ACS Case Reviews in Surgery*. 2024;4(5):16-19.

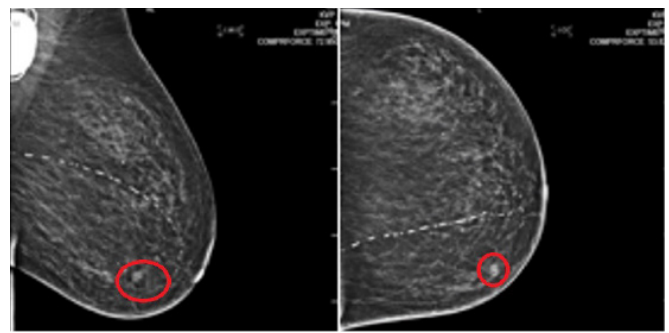
Case Description

It is well documented that cancer development is a significant cause of morbidity and mortality following solid organ transplantation.¹ This is thought to be multifactorial, potentially associated with the length of immunosuppression rather than the specific medications used.¹ However, some previous studies suggest that breast cancer does not show a higher occurrence in transplant recipients. Nevertheless, outcomes are generally less favorable.¹⁻³ Although breast cancer is the most prevalent cancer in women from developed nations, there is a noticeable lack of surgical management guidelines for breast cancer in kidney transplant recipients, which likely can be attributed to the limited number of affected patients.

In this report, we present a rare case of breast cancer diagnosed in a patient ten years after undergoing a kidney transplant. The patient is a 73-year-old female with a history of end-stage renal disease secondary to hypertension and diabetes that resulted in a deceased donor kidney transplant ten years prior. Her history was also notable for endometrial cancer, for which she underwent unilateral oophorectomy and hysterectomy, and cardiovascular disease requiring left chest pacemaker implantation. She was referred for evaluation of a screen-detected left breast lesion (Figure 1). The abnormality measured 1.0 × 0.8 × 0.8 cm. An ultrasound-guided core needle biopsy was performed, which revealed a left breast invasive ductal carcinoma (IDC). Hormone receptor status noted the tumor to be estrogen receptor (ER) negative, progesterone receptor (PR) negative, and human epidermal growth factor receptor (HER2) negative. After discussion during multidisciplinary rounds, neoadjuvant chemotherapy was forgone given her kidney transplant status on immunosuppression and the small size of the tumor. The surgical options were discussed with the patient, including left breast mastectomy with or without reconstruction and breast conservation with subsequent radiation therapy. The patient elected to have breast-conserving surgery (BCS), which was performed along with sentinel lymph node biopsy (SLNB). The surgery was well-tolerated without immediate complications. Final pathology demonstrated a 1.3 cm tumor, node-negative, IDC with negative margins (T1c, N0, M0).

Adjuvant chemotherapy was attempted but not tolerated by the patient. She was referred to radiation oncology for daily adjuvant radiotherapy, and she received 30 treatments truncated slightly due to skin toxicities.

Figure 1. Diagnostic Mammography Demonstrating Left Breast Focal Asymmetry in Anterior Lower Inner Quadrant. Published with Permission



She was hospitalized for urinary sepsis, which was believed to be unrelated to her breast cancer treatment. She has been seen in follow-up and, thus far, has had no signs of locoregional recurrence or distant metastatic disease. Her kidney function has fully recovered without experiencing graft rejection, and her immunosuppressive medication regimen was maintained consistently both before and after the surgery.

Discussion

The incidence of cancer after kidney transplantation has increased in recent years, likely due to the increase in patient survival from more effective immunosuppressive agents. However, several studies have noted that the incidence of breast cancer in kidney transplants is either reduced or comparable to the general population, suggesting that immunosuppression may not increase the risk of developing breast cancer after transplantation.² One retrospective study from a single institution examined 2,139 patients with chronic renal failure who underwent kidney transplantation between 1999 and 2011. It found 142 patients who developed post-transplant malignancy; 11 were diagnosed with breast cancer. Their prognosis was compared to the 2554 breast cancer patients from the same time and was comparable to that of the general population in terms of five-year survival.⁶ Another single institution study found that 9 of 750 kidney transplant patients developed breast cancer. Following the breast cancer diagnosis, no adjustment of immunosuppressant agents was made.⁴

Few studies have explored the treatment of breast cancer in patients who have undergone solid organ transplants, especially regarding surgical approaches. A review of three separate single-institution studies conducted by Self et al., Kwak et al., and Kato et al. reveals that out of 34 kid-

ney transplant patients diagnosed with breast cancer, 14 underwent BCS. It is noteworthy that only one patient underwent breast-conserving surgery (BCS) along with sentinel lymph node biopsy (SLNB). This can be attributed to SLNB not being commonly practiced during the time frame of these studies (Table 1).⁴⁻⁶ Nine patients received adjuvant chemotherapy, and none experienced acute rejection of the kidney transplant. Four patients underwent both chemotherapy and radiation therapy. Of note, no cases of triple-negative breast cancer were documented following kidney transplantation.

particularly unique challenge as the patient presented with an aggressive subtype of breast cancer ten years after kidney transplantation. The existing literature lacks specific guidelines for adjuvant chemotherapy, surgical, and radiation therapy management in post-kidney transplant breast cancers. However, insights from various single-institution retrospective reviews suggest that these cancers may be managed similarly to the general population.

Table 1. Multi-Study Comparison of Management of Post-Transplant Breast Cancer

Study, N = number of PTBC patients	Procedures	Chemotherapy	Radiation Therapy	Cancer Subtypes
Kato et al. N = 9	7 BCS 2 MRM	--	--	7 IDC 2 DCIS
Self et al. N = 14	6 BCS 8 MRM	4	4	12 IDC 2 DCIS
Kwak et al. N = 11	1 BCS with SLNB 5 MRM 4 SM with SLNB 1 excisional biopsy	5	--	--

Reducing the dose of immunosuppressant drugs is controversial. It does not appear to offer any benefit in reducing the incidence of breast cancer, as breast cancer is not considered to be immunogenic. Triple-negative breast cancer, however, is considered to have some immunogenicity compared to other subtypes.^{1,7} The ideal management of immunosuppressive agents in solid organ transplant patients who develop breast cancer is uncertain but likely can be extrapolated from the general population.² In the kidney transplant population, complete surgical removal continues to be the standard of care, similar to the general population. However, there is ongoing debate about the use of chemotherapy in more biologically aggressive breast cancers. It is important to note that chemotherapeutic agents can be nephrotoxic, so assessing renal function before administration is crucial.

Conclusion

Breast cancer in the kidney transplant population is a rare occurrence with an incidence that is comparable to the general population despite the overall higher incidence of carcinomas in transplant patients. Our case presents a

Lessons Learned

There is a lack of literature addressing how to manage breast cancer following kidney transplantation. At present, the surgical management of breast cancer in the kidney transplant population can be extrapolated from the general population. While immunosuppression often does not need to be reduced or discontinued, the nephrotoxicity of chemotherapeutic agents should be considered before administration.

References

- Jeong IJ, Lee SG, Kim YH, et al. Characteristics and prognosis of breast cancer after liver or kidney transplantation. *Breast Cancer Res Treat.* 2018;167(1):101-106. doi:10.1007/s10549-017-4504-1
- Wong G, Au E, Badve SV, Lim WH. Breast Cancer and Transplantation. *Am J Transplant.* 2017;17(9):2243-2253. doi:10.1111/ajt.14368
- Buell JF, Hanaway MJ, Trofe J, et al. De novo breast cancer in renal transplant recipients. *Transplant Proc.* 2002;34(5):1778-1779. doi:10.1016/s0041-1345(02)03063-4

4. Kato T, Kakuta Y, Yamanaka K, et al. Early diagnosis and treatment of breast cancer in Japanese kidney transplant recipients: a single center experience. *Springerplus*. 2015;4:196. Published 2015 Apr 25. doi:10.1186/s40064-015-0946-2
5. Self M, Dunn E, Cox J, Brinker K. Managing breast cancer in the renal transplant patient: a unique dilemma. *Am Surg*. 2006;72(2):150-153.
6. Kwak HY, Chae BJ, Bae JS, Jung SS, Song BJ. Breast cancer after kidney transplantation: a single institution review. *World J Surg Oncol*. 2013;11:77. Published 2013 Mar 22. doi:10.1186/1477-7819-11-77
7. Liu Z, Li M, Jiang Z, Wang X. A Comprehensive Immunologic Portrait of Triple-Negative Breast Cancer. *Transl Oncol*. 2018;11(2):311-329. doi:10.1