

# Postrecovery Complications of Gastrointestinal Abscesses and Perforations in COVID-19 Patients

**AUTHORS:**

Shen J; Nwoke F; Lohr C III; Fletcher S;  
DeMartini S; Nagubandi R

**CORRESPONDING AUTHOR:**

Ravi Nagubandi, MD, FRCS (I), FACS  
Oroville Hospital Department of Surgery  
2767 Olive Highway  
Oroville, CA, 95966  
Phone: (530) 532-8161  
Email: rnagubandi@orohosp.com

**AUTHOR AFFILIATION:**

Oroville Hospital Department of Surgery  
California North State University  
Oroville, CA 95966

|                   |  |
|-------------------|--|
| <b>Background</b> | A 69-year-old man presented with small intestinal abscesses during the weeks immediately following respiratory COVID-19 recovery, confirmed via nasopharyngeal testing.  |
| <b>Summary</b>    | <p>The patient, a 69-year-old male, presented with severe abdominal pain two weeks after a positive COVID-19 test and associated symptoms. His follow-up nasopharyngeal COVID-19 test was negative. CT demonstrated enteritis and microperforation, and he was managed conservatively with antibiotics and discharged after three days. However, he returned the following week with worsening abdominal pain and peritoneal signs. Follow-up CT showed a jejunal abscess and was drained by interventional radiology. Despite drainage, peritoneal signs persisted, and surgical intervention was indicated. Exploratory laparotomy was performed with drainage of abscess, resection of the jejunal mass, and primary jejunojejunal anastomosis. He recovered symptomatically, but the development of an enterocutaneous fistula complicated his postop course.</p> <p>Since the outbreak of the novel coronavirus disease 2019 (COVID-19) in December 2019, various acute clinical manifestations and chronic complications have been reported worldwide. While there is a prevalence of acute gastrointestinal symptoms such as diarrhea, abdominal pain, and vomiting in COVID-19 patients, long-term gastrointestinal complications have not been well documented.</p> |
| <b>Conclusion</b> | COVID-19-related complications are still being investigated. We present a case of severe gastrointestinal complications in the weeks immediately following COVID-19 infection, potentially suggesting a causal relationship between SARS-CoV-2 infection and the complications. Therefore, attentive surveillance and evaluation for gastrointestinal symptoms following the acute course of COVID-19 infection is recommended.  |
| <b>Key Words</b>  | COVID-19; SARS-CoV-2; abscess; perforation   |

**DISCLOSURE STATEMENT:**

The authors have no conflicts of interest to disclose.

**FUNDING/SUPPORT:**

The authors have no relevant financial relationships or in-kind support to disclose.

**RECEIVED:** July 25, 2021

**REVISION RECEIVED:** January 26, 2022

**ACCEPTED FOR PUBLICATION:** February 7, 2022

**To Cite:** Shen J; Nwoke F; Lohr C III; Fletcher S; DeMartini S; Nagubandi R. Postrecovery Complications of Gastrointestinal Abscesses and Perforations in COVID-19 Patients. *ACS Case Reviews in Surgery*. 2022;3(8):1-4.

## Case Description

With the outbreak of COVID-19 in December 2019, efforts to understand this disease have gained rapid momentum. An increase in gastrointestinal symptoms such as diarrhea rose from 20% to 53% after March 2020.<sup>1</sup>

A genetic study on in vitro infectivity of SARS-CoV-2 demonstrated the viral affinity for angiotensin-converting enzyme II (ACE2) as the site of attachment allowing for viral entry.<sup>2</sup> It is also shown that ACE2 proteins are expressed in the intestinal mucosa, and these cells were confirmed to replicate SARS-CoV-2.<sup>3</sup> Furthermore, SARS-CoV-2 RNA can be isolated from stool samples in 53.42% of infected patients, with up to 23.39% of patients having persistently positive stool RNA following negative nasopharyngeal tests.<sup>4</sup> These results indicate SARS-CoV-2 infiltration in the intestinal tract and suggest the possibility for dissemination in time for an infectious presentation.

A few case reports suggested severe gastrointestinal complications during an active COVID-19 infection, including but not limited to small and large bowel perforations and splenic abscesses.<sup>5-7</sup> Given the evidence of gastrointestinal involvement and variability in SARS-CoV-2 clearance in different organ systems, we suspect implications of gastrointestinal complications in the period immediately following recovery from respiratory SARS-CoV-2.

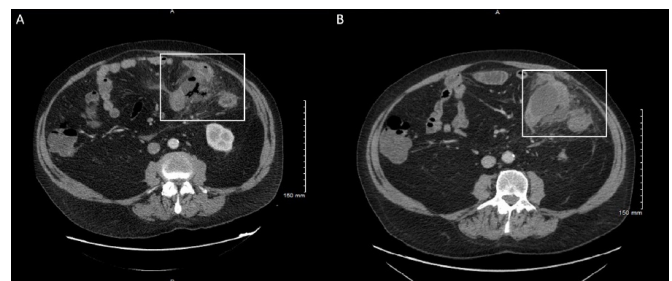
A 69-year-old man who presented with shortness of breath, cough, abdominal pain, nausea, vomiting, and diarrhea tested positive for SARS-CoV-2 on 12/03/2020. He was treated conservatively as an outpatient. On 12/15/2020 (two weeks following his initial presentation), he returned to the ED for worsening left lower and middle quadrant pain for three days. A nasopharyngeal COVID-19 test was negative on this encounter. A physical exam showed abdominal distension with tenderness but no acute peritoneal signs. CT abdomen and pelvis found free intraperitoneal air suggesting micro-perforation (Figure 1A). Patchy diffuse ground-glass infiltrates were seen in the lungs, likely secondary to previous COVID-19 infection. Conservative management with IV piperacillin-tazobactam was adequate in alleviating his symptoms, and he was discharged after three days with outpatient oral amoxicillin-clavulanic acid.

The patient returned to the ED on 12/23/2020 with excruciating abdominal pain, and his abdomen was diffusely tender with guarding. Abdominal CT showed a 5 cm interval abscess next to the jejunum, a progression from previously imaged micro-perforations (Figure 1B).

Interventional radiology drained the abscess the following day, and cultures were positive for MRSA and normal skin flora. Vancomycin was started. However, over the week, the drain began to yield enteric content and localized peritoneal signs developed. An exploratory laparotomy with extensive lysis of adhesions, drainage of abscess, mobilization of the splenic flexure of the colon, and resection of the jejunal mass with primary jejunojunctional anastomosis was performed one week later. Histological examination demonstrated granulation tissue and inflammatory changes consistent with a perforated abscess and no evidence of malignancy. His symptoms improved over several days, and he was discharged on 01/01/2021.

The patient was subsequently readmitted for a newly developed, high-output enterocutaneous fistula after surgical staple removal. The patient has been managed conservatively as an outpatient as the fistula outputs dwindle.

**Figure 1.** CT with Contrast. Published with Permission



A) CT showing intraperitoneal free air suggesting microperforations; and B) days later, showing 5 cm interval abscess adjacent to jejunum.

## Discussion

This case confronts the possibility of lingering severe gastrointestinal complications following the resolution of the respiratory tract SARS-CoV-2 virus. The pathophysiology behind gastrointestinal micro-perforation and abscess formation may be unclear since much of the current understanding of SARS-CoV-2 complications in the human body remains unknown. However, we hypothesize that the immunological alterations and changes in gut microbiome diversity contribute to the pathophysiological process that renders the bowel vulnerable to inflammation, injury, perforation, and/or abscess formation.

Given the consensus that SARS-CoV-2 infects via ACE2 enzyme, a point of exploration is the alteration of the ACE2 enzyme in the gastrointestinal tract. It has been established in a study that SARS-CoV-infected cells tend to have a downregulation in ACE2 expression.<sup>8</sup> A decrease in ACE2 enzyme expression via gene knockout in mice shows an increased vulnerability to intestinal inflammation related to epithelial damage. Furthermore, by transplanting fecal matter from the knockout mice into wild-type mice, the recipients of the fecal transplant had a higher risk of developing severe colitis.<sup>9</sup> The ability to transfer such vulnerability via fecal matter indicates that alteration of the microbiome may be partially responsible for abscess formation.

It was also discovered that COVID-19 patients tend to have significantly decreased bacterial diversity in their gut microbiomes. Opportunistic pathogens such as *Streptococcus*, *Rothia*, *Veillonella*, and *Actinomyces* are increased in the microbiome of COVID-19 patients, whereas beneficial microbes experienced a relative reduction.<sup>10</sup> The combination of increased susceptibility to gastrointestinal inflammation following the downregulation of ACE2 enzymes and the relative proliferation of opportunistic bacteria are likely major contributing factors responsible for the development of gastrointestinal abscesses in the case described.

Thus far, our research has only found a single report discussing the postacute phase of COVID-19-related severe gastrointestinal perforation.<sup>11</sup> In contrast, several before-mentioned case reports correlate gastrointestinal complications during the active phase of infection.

Given the risk of abscess formation in patients who have recently recovered from COVID-19, we recommend evaluating with a high suspicion index and monitoring those who present with gastrointestinal symptoms. Although this case presents with abscess formation, patients may be susceptible to other complications due to their immunological and physiological disturbances. We encourage surveillance of symptoms even after respiratory SARS-CoV-2 resolution.

In retrospect, would an early exploratory laparotomy on the initial diagnosis of possible micro-perforation have changed the course of patient recovery? When confronted with “contained air adjacent to the intestinal wall” on CT, our medical decision-making was swayed by the initial mild physical signs of localized abdominal tenderness without apparent signs of generalized peritonitis.

In addition, his recent COVID pneumonia raised concerns for risk under general anesthesia. Thus, at the time, our decision favored a conservative approach with antibiotics, assuming that the free air was self-contained. However, with further research demonstrated in this case report, we recognize that intestinal immunomodulation and the inflammatory changes after the resolution of COVID pneumonia may challenge our initial understanding of disease severity. While it is difficult to deduce whether the gastrointestinal sequelae of the population who are post-COVID are preventable with early operative intervention based on a single case report, we entertain the idea that early aggressive interventions should be considered a viable option.

## Conclusion

An increasing range of COVID-19 symptoms and complications are still being discovered. We present a patient who developed an enteric abscess after the acute phase of COVID-19 symptoms. Thus, we recommend close surveillance of post-recovery COVID-19 patients who present with gastrointestinal symptoms.

## Lessons Learned

SARS-CoV-2 infection may precipitate late-phase involvement in the gastrointestinal tract and present complications even after respiratory symptom resolution. With considerations for early operative intervention, careful surveillance of abdominal symptoms may prevent debilitating complications because these patients have the potential for acute decline due to their maladaptive inflammatory gastrointestinal physiology.

## References

1. Burke RM, Killerby ME, Newton S, et al. Symptom Profiles of a Convenience Sample of Patients with COVID-19 - United States, January-April 2020. *MMWR Morb Mortal Wkly Rep.* 2020;69(28):904-908. Published 2020 Jul 17. doi:10.15585/mmwr.mm6928a2
2. Zhou P, Yang XL, Wang XG, et al. A pneumonia outbreak associated with a new coronavirus of probable bat origin. *Nature.* 2020;579(7798):270-273. doi:10.1038/s41586-020-2012-7
3. Hamming I, Timens W, Bulthuis ML, Lely AT, Navis G, van Goor H. Tissue distribution of ACE2 protein, the functional receptor for SARS coronavirus. A first step in understanding SARS pathogenesis. *J Pathol.* 2004;203(2):631-637. doi:10.1002/path.1570

4. Xiao F, Tang M, Zheng X, Liu Y, Li X, Shan H. Evidence for Gastrointestinal Infection of SARS-CoV-2. *Gastroenterology*. 2020;158(6):1831-1833.e3. doi:10.1053/j.gastro.2020.02.055
5. De Nardi P, Parolini DC, Ripa M, Racca S, Rosati R. Bowel perforation in a Covid-19 patient: case report. *Int J Colorectal Dis*. 2020;35(9):1797-1800. doi:10.1007/s00384-020-03627-6
6. Schwab K, Hamidi S, Chung A, et al. Occult Colonic Perforation in a Patient With Coronavirus Disease 2019 After Interleukin-6 Receptor Antagonist Therapy. *Open Forum Infect Dis*. 2020;7(11):ofaa424. Published 2020 Sep 12. doi:10.1093/ofid/ofaa424
7. Al-Ozaibi LS, Alshaikh MO, Makhdoom M, Alzoabi OM, Busharar HA, Keloth TR. Splenic Abscess: An Unusual Presentation of COVID-19?. *Dubai Medical Journal*. 2020;1-4. Published 2020 Sep 7. doi:10.1159/000509644
8. Kuba K, Imai Y, Rao S, et al. A crucial role of angiotensin converting enzyme 2 (ACE2) in SARS coronavirus-induced lung injury. *Nat Med*. 2005;11(8):875-879. doi:10.1038/nm1267
9. Hashimoto T, Perlot T, Rehman A, et al. ACE2 links amino acid malnutrition to microbial ecology and intestinal inflammation. *Nature*. 2012;487(7408):477-481. Published 2012 Jul 25. doi:10.1038/nature11228
10. Gu S, Chen Y, Wu Z, et al. Alterations of the Gut Microbiota in Patients With Coronavirus Disease 2019 or H1N1 Influenza. *Clin Infect Dis*. 2020;71(10):2669-2678. doi:10.1093/cid/ciaa709
11. Banerjee S, Singh SK, Thakur SD. Pneumomediastinum, Tension Pneumoperitoneum Secondary to Bowel Perforation in Post COVID-19 Patient: A Case Report. *Ann Clin Case Rep*. 2021; 6: 1915